

A Cloaca in Male, Not Fistula in Perineum

Naser El-Mefleh*

Department. of Pediatric Surgery, National Hospital, Aleppo, Syira
Department of Pediatric Surgery, Bab Al Hawa Hospital, Edleb, Syria

*Corresponding author:

El-Mefleh Naser,
E-mail: dr.naser1989@hotmail.com
Mailing Address: NECMETTIN MAH.
BEDIR SOK. NO. 33 79000 KILIS MERKEZ / KILIS
TURKEY, Telephone Number: 00905356035438
ORCID: 0000-0003-4766-4093

Received: 06 Apr 2024

Accepted: 27 May 2024

Published: 31 May 2024

J Short Name: AJSCCR

Copyright:

©2024 El-Mefleh NA, This is an open access article distributed under the terms of the Creative Commons Attribution License, which permits unrestricted use, distribution, and build upon your work non-commercially.

Keywords:

Cloaca; Male; Neonate; Perineal; Hypospadias

Citation:

El-Mefleh NA. A Cloaca in Male, Not Fistula in Perineum. *Ame J Surg Clin Case Rep.* 2024; 7(14): 1-3

1. Abstract

Cloacal malformation is a rare and is invariably referred only to females. Here is report of a very rare case of male cloaca (MC) variant in neonate who presented with absent anal opening along with passage of urine and meconium from an abnormal opening in the perineum.

2. Introduction

Cloacal malformation is a very rare entity with a frequency of 1:50,000–1,25,000 newborn [1]. It is invariably referred only to females [2]. There are only a few cases of MC reported in the recent literature. In addition, there is a lack of consensus regarding the entity in males and its management [1,4,5,6]. We share an extremely rare case management of variant.

3. Case Report

A full term male neonate, presented to us with signs of simple imperforated anus with perineal fistula. Perineal examination revealed absent anal opening and presence of a single midline anterior perineal opening at the proximal part of the scrotum. Urine was seen coming out of the perineal opening along with amount of

thick meconium. On careful inspection, there was a small cavity underneath the perineal opening. Testes were bilaterally descended and severe chordee with perineal hypospadias along with penoscrotal transposition was present. An initial VACTERL workup was done. A stoma in beginning of the sigmoid colon beginning was performed and after opening through meconium line we saw two openings, one was urethral meatus of severe hypospadias anteriorly and other was anal fistula posteriorly placed (Figure 1A).

A simple anterior sagittal anorectoplasty was performed; common channel was separated, and closing of scrotal hypospadias with some sutures on catheter (Figure 1B). The patient did well post-operatively.

In age of 9 months old, we operated anoplasty by stimulator and then repairing proximal hypospadias with STAC 1 (Figure 2).

And after another 6 months we did a second stage of hypospadias repair and colostomy closing (Figure 3).

The child now is 4.5-year-old (Figure 4). Urethral stone (simple anterior urethral stenosis) was managed before 8 months by cystoscopy and laser.

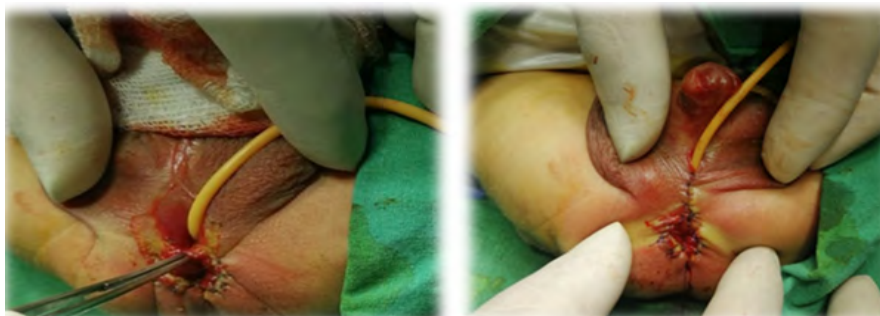

Figure 1: a: appearance after opening meconium line, b: simple anoplasty and simple perineal hypospadias closing

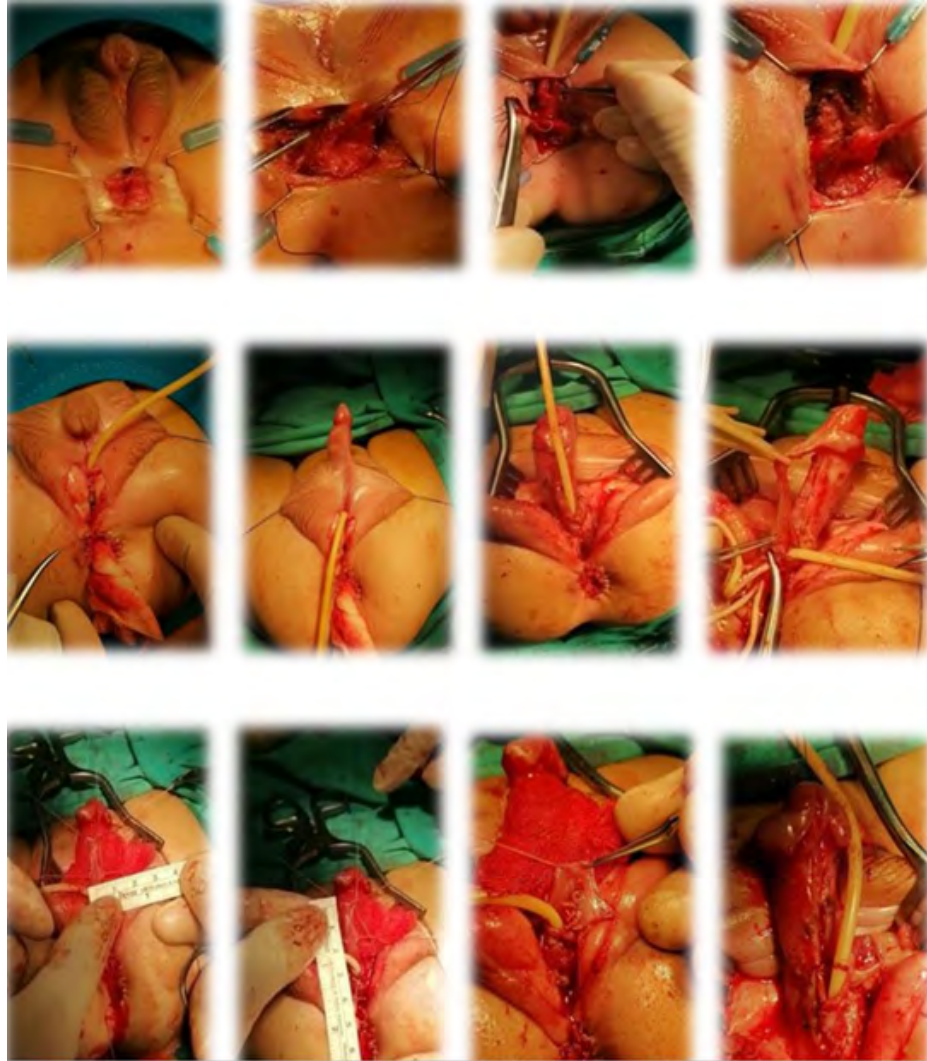


Figure 2: steps of the main procedure

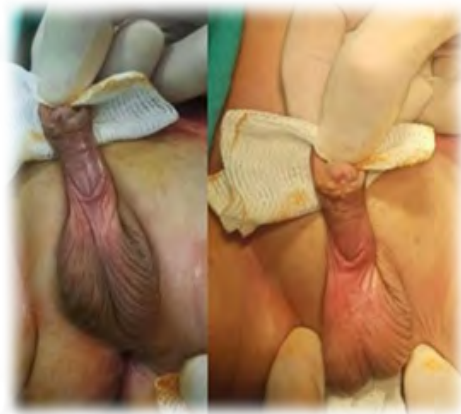

Figure 3: The appearance after STAC 1

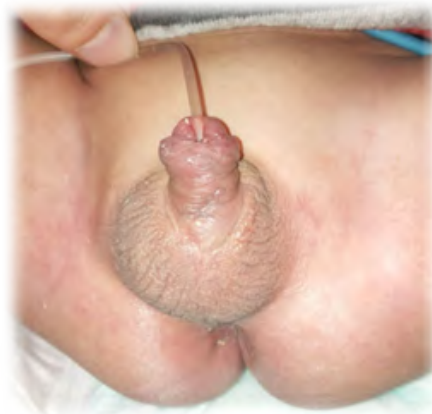

Figure 4: The last appearance

4. Discussion

The cloaca is a single common channel which is formed at the 3rd week at the tail fold through the confluence of the allantois and the hindgut. Series of events lead to its partition and separation of urinary system, genital tract, and anorectum [4,6]. Persistent cloaca is conventionally defined as “a single perineal orifice formed as a confluence of urinary, genital, and rectal systems ending in a common channel of varying lengths [2,7]. According to Livingston et al., all patients with persistent cloaca are female and have normal ovaries [7]. Most of the surgical literature refers only to female as having cloacal defects. However, there is every chance of the development of cloacal anomalies in males as during embryogenesis; both sexes have to pass through the stage of a cloaca [1,4].

Male cloacal variants were defined as a defect in the male with a single perineal opening, in which rectum and urinary tract, with or without vagina, converge into one common channel [1]. Male cloaca was referred as a single opening in perineum for passage of urine and meconium, with common channel of varying lengths containing separate openings for the urinary tract (anteriorly) and the rectum (posteriorly) [5]. Male cloacal variants may present in the neonatal period and up to 5 years [1,5]. Late presentation (28 years) has also been reported [1]. Single opening may be located anywhere from anterior perineum to the tip of glans [1,5]. Length of the common channel ranged from 0.5 to 8 cm [1]. Vaginal remnant (not seen in our case) has been reported in 50% cases of male cloacal variants [1]. Genital abnormalities are severe in cloacal malformation, and proximal hypospadias is a common finding [1,5]. Renal abnormalities have also been reported [1].

As Peña et al., the posterior cloaca refers to a malformation in which the urethra and vagina are fused, forming a urogenital sinus that deviates posteriorly to open in the anterior rectal wall or immediately anterior to the anus [8,9]. The rectum is essentially normal or may be minimally anteriorly mislocated [8,9]. Hendren described posterior cloaca as rare cloacal malformation in boys [10]. As the common channel in cloaca can deviate anteriorly or posteriorly [8] thus posterior cloaca in boys as reported by Hendren could be a subset of a male cloacal malformation. The differences in cloacal anatomy are a result of the divergent differentiation of the genitourinary tracts in the two sexes. The spectrum of cloacal abnormalities may result from a partial to complete urorectal septum malformation [6].

The differential diagnosis of male cloaca is anorectal malformation with rectourethral fistula (or rectovesical fistula) with proximal (perineal) hypospadias. In males, the spectrum of cloacal abnormalities is difficult to recognize [4]. The presence of common channel should be confirmed by careful visual examination [1]. In addition, a search for the presence of any vaginal remnant should be performed [1]. Colostomy as part of initial management [5], but definitive management consists of either posterior/anterior

sagittal anorectoplasty and urethroplasty, posterior sagittal anorectourethroplasty or perineal urethrostomy and anoplasty followed by urethroplasty [5]. Common channel should be preserved at the time of anorectoplasty to function as male urethra at the time of urethroplasty. Furthermore, colostomy closure should be undertaken after complete severe hypospadias to prevent ascending urinary tract infection and soiling. Mortality is not rare (because of associated multiple anomalies) [2].

5. Conclusion

A high index of suspicion for the presence of common channel should be present in a male patient of ARM with single perineal opening associated with urogenital abnormalities and big advice to catheter the urethra always before anoplasty and urethroscopy if there is suspicion.

References

1. Banu T, Chowdhury TK, Hoque M, Rahman MA. Cloacal malformation variants in male. *Pediatr Surg Int.* 2013; 29: 677-82.
2. Hendren WH. Cloaca, the most severe degree of imperforate anus: Experience with 195 cases. *Ann Surg.* 1998; 228: 331-46.
3. Major SG. Persistence of the cloaca: Report of a case. *Minn Med.* 1929; 12: 96-7.
4. Qureshi F, Jacques SM. Cloacal abnormalities in male fetuses. *J Ultrasound Med.* 2012; 31: 2046-7.
5. Sharma S, Gupta DK. Male cloaca malformation: Rare variant of anorectal malformation. *Pediatr Surg Int.* 2015; 31: 747-52.
6. Wheeler PG, Weaver DD. Partial urorectal septum malformation sequence: A report of 25 cases. *Am J Med Genet.* 2001; 103: 99-105.
7. Livingston JC, Elicevik M, Breech L, Crombleholme TM, Peña A, Levitt MA, et al. Persistent cloaca: A 10-year review of prenatal diagnosis. *J Ultrasound Med.* 2012; 31: 403-7.
8. Peña A, Kessler O. Posterior cloaca: A unique defect. *J Pediatr Surg.* 1998; 33: 407-12.
9. Peña A, Bischoff A, Breech L, Loudon E, Levitt MA. Posterior cloaca – Further experience and guidelines for the treatment of an unusual anorectal malformation. *J Pediatr Surg.* 2010; 45: 1234-40.
10. Holschneider AM, Scharbatke H. Persistent cloaca-clinical aspects. In: Holschneider AM, Hustson JM, editors. *Anorectal Malformations in Children: Embryology, Diagnosis, Surgical Treatment, Follow-Up.* 1st ed. Berlin, Heidelberg: Springer-Verlag. 2006; 201-8.