

Urgent Distal Carpectomy Following Traumatic Wrist Injury: A Case Report

Eglīte E^{1*}, Kalva K^{2,3}, Neļjodovs V⁴, Platkājis A², Nulle K³, Zdanovskis N^{2,3}, Kratovska A^{2,3,5}, Naglis R^{2,3,5} and Tiltiņa L^{2,3,5}

¹Riga Stradins University, Faculty of Medicine, LV-1007 Riga, Latvia

²Department of Radiology, Riga Stradiņš University, LV-1007 Riga, Latvia

³Department of Radiology, Riga East Clinical University Hospital, LV-1038 Riga, Latvia

⁴Riga Stradiņš University; Latvian Plastic Reconstructive and Microsurgery Center, LV-1024 Riga, Latvia;

⁵Emergency Department, Riga East Clinical University Hospital, LV-1038 Riga, Latvia

*Corresponding author:

Everita Eglīte,
Riga Stradins University, Faculty of Medicine,
LV-1007 Riga, Latvia

Received: 06 Apr 2024

Accepted: 24 May 2024

Published: 29 May 2024

J Short Name: AJSCCR

Copyright:

©2024 Eglīte E, This is an open access article distributed under the terms of the Creative Commons Attribution License, which permits unrestricted use, distribution, and build upon your work non-commercially.

Citation:

Eglīte E. Urgent Distal Carpectomy Following Traumatic Wrist Injury: A Case Report. *Ame J Surg Clin Case Rep.* 2024; 7(14): 1-5

Keywords:

Carpectomy; Hand injury; Carpal bones

1. Abstract

1.1. Background: Distal row carpectomy (DRC) is a surgical procedure involving the removal of the distal row of carpal bones. It is typically considered a salvage procedure, although documentation, particularly in trauma cases, is limited.

1.2. Case report: Case report details a 52-year-old man who presented with a traumatic injury to his right hand in the emergency department. Clinical and radiographic assessments revealed a fully dislocated II-V metacarpal bones with fractures, joint damage, and extensive soft tissue damage in the patient's right hand, with complete damage to tendons and dorsal branches of the radial artery.

Due to the loss of articulation surfaces on the metacarpal and distal carpal bones, the decision was made to remove the distal carpal row and fixate the remaining bones with Kirschner wires. Additionally, anastomosis of the damaged extensor tendons and nerves was performed. Postoperative radiographs confirmed physiological alignment of the proximal carpal row and metacarpal bones, distal carpal row fixation. The postoperative plan included wound management, immobilization with a plaster splint, antibacterial therapy, suture removal in 2-3 weeks, Kirschner wire removal in 8 weeks, and a final follow-up in 6 months.

1.3. Conclusions: This case report showcases an infrequently documented distal row carpectomy, resulting in satisfactory clinical outcomes for a patient with a subtotal wrist amputation.

2. Background

Distal Row Carpectomy (DRC) is a surgical intervention characterized by the complete removal of the distal row of carpal bones.

It is often used as a salvage surgery for severe carpal trauma. DRC is used for complex and shattering wrist injuries, like wrist amputations [1]. Additionally, DRC is advised for addressing giant cell tumors in the carpus and triquetrum, demonstrating successful outcomes in their management [2].

Complex wrist injuries, including fracture dislocations, commonly culminate in post-traumatic arthrosis. Individuals affected by such injuries often experience significant wrist pain and functional impairment, with a considerable number eventually undergoing total arthrodesis as a solution [1,3].

To address the limitations of total arthrodesis, alternative treatment strategies have been explored. Proximal row carpectomy (PRC) is a well-established procedure for managing wrist conditions, with numerous reports in the literature detailing its outcomes and effectiveness [4,5]. To the best of our knowledge, there is only limited information on distal carpectomy as a treatment option, with few reports discussing its use.

The authors present a rare and specific case involving a person with a right hand injury due to work trauma, treated with the less frequently reported distal row carpectomy.

3. Case Report

The 52-year-old male was hospitalized acutely after sustaining an injury to his right hand while working with a meat mixer. The patient reported pain, bleeding from the wound, tingling sensations, and an inability to move the hand. Objective examination revealed a pulse rate of 94 beats per minute, a blood pressure of 161/87 mmHg and a respiratory rate of 14 breaths per minute with normal

vesicular breathing sounds. During the examination of the patient, it was found that there was a partial amputation of the right hand at the II-V carpometacarpal (CMC) joints level, along with venous stasis (Figure 1 A, B).

The bleeding from the palm was managed, and injuries to both the flexor and extensor tendons were noted. The patient retained movement in the thumb, but there was sensory damage to the fingers (II-V) involving the radial and median nerves. The patient denied any history of adjacent diseases, previous surgical interventions, or allergies. Laboratory findings included ethanol levels below 0.1 g/L, a C-reactive protein (CRP) level of 0.2 mg/L, and a glucose level of 9.5 mmol/L.

The patient underwent an x-ray of the right hand in both posteroanterior (PA) and Lateral-Lateral (LL) projections (Figure 2 C, D). The images revealed a full dislocation of the II-V metacarpal bone in the dorsal direction, accompanied by fracture fragments of the metacarpal bones. Additionally, there were well-defined fractures of the carpal bones in the 2nd row of the hand, subluxation of the first metacarpal dorsally, indistinct carpo-metacarpal joint spaces, and significant soft tissue damage in the wrist and carpal bone region.

After a detailed examination, it was found that the joint surface of os hamatum and os capitatum is completely absent, while os trapezium and os trapezoideum are missing 50% of it. The flexors and extensor pollicis longus tendon was found to be preserved, while the other wrist and digits extensor tendons suffered complete tear. Complete damage to the dorsal branch of the radial artery, cephalic and basilic veins was observed. Radial, median, and ulnar nerve sustained a traction injury with no transverse damage.

Given the severity of the damage (Figure 3 E, F, G), preserving the distal carpal row wasn't considered a clinically relevant option due to the loss of articulation surfaces and the necessity for bone shortening. The final decision was to proceed immediately with surgery, including revascularization (using one artery and two veins), distal carpectomy, and fixation with Kirschner wire, anastomosing damaged tendons and nerves.

The patient underwent brachial plexus anesthesia. Following a re-assessment of the wrist injury, an osteotomy was performed under tourniquet control. Subsequently, a distal carpectomy was conducted, involving the excision of the os hamatum, os capitatum, os trapezoideum, and os trapezium.

During the patient's operative treatment, tenolysis were performed on the extensor carpi ulnaris, extensor digiti minimi, II-V extensor communis, extensor pollicis proprius, extensor pollicis longus, extensor carpi radialis longus et brevis. Due to resection of natural insertion for extensor carpi ulnaris and extensor carpi radialis brevis, they were transfixed with bone anchors accordingly to the base of the 2nd and 5th metacarpal bones. Additionally, tenolysis was carried out on the flexor pollicis longus, II-V flexor digitorum superficialis, II-V flexor digitorum profundus, and flexor carpi radialis. Neurolysis of the dorsal branch of the radial nerve, ulnar nerve, and median nerve was also executed. (Figure 4 H, I, J).

Kirschner wires are used to secure (I, II, III, IV, V) MCC to the bones of the proximal carpal row, passing through the scapholunate joint (Figure 5 K, L).

The radial artery, cephalic and basilic veins were sutured, while employing the "end-to-end" technique to establish connections between two subcutaneous veins, contributing to the restoration of optimal blood circulation in the hand. Following the surgery, a sterile bandage was applied, and the right wrist was immobilized using a plaster splint.

The patient's treatment plan included wound care every 2-3 days along with regular application of antiseptic solution to the wire entry site at the same interval. Sutures were removed after 2-3 weeks, and the applied plaster immobilization was used for 6 weeks. Furthermore, the patient was prescribed a 14-day course of antibacterial therapy (Amoksiklav) and, if necessary, pain management.

The patient's recovery has shown significant progress, as evidenced by positive radiographic findings at both the two-month and six-month post-surgery intervals, with no adverse healing complications noted (Figure 6 M, N). During the six-month evaluation, the Lyon Wrist Clinical Evaluation Form was utilized to assess wrist function and strength, resulting in a fair grade score of 63 for the patient. The reduced wrist flexion and extension was observed during this assessment, highlighting specific areas that necessitate targeted rehabilitation.

Despite these challenges, the patient's hand has achieved full recovery six months after undergoing surgery, which included a distal carpectomy (Figure 7 O, P). This favorable outcome, coupled with the preservation of sensation and mobility, highlights the effectiveness of the treatment approach employed.

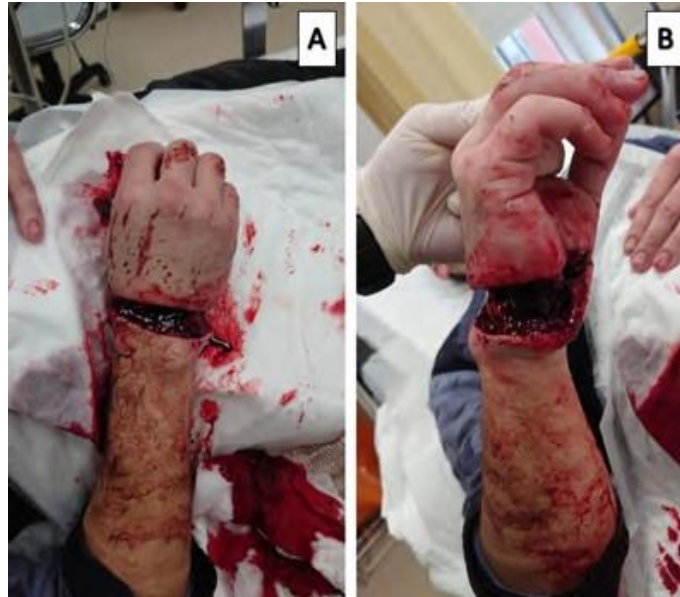

Figure 1: Preoperative Clinical Image. Anterior (A) and lateral (B) views reveal a subtotal amputation at the right hand's wrist level, with apparent venous stasis. Remarkably, feeling in the fingers is preserved despite the severity of the injury.

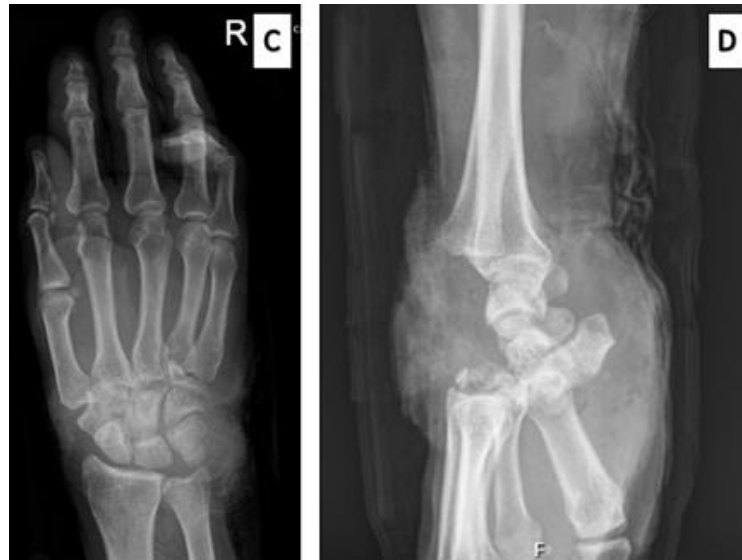

Figure 2: (C) In the posterior-anterior (PA) radiograph of the right wrist, fractures in the 2nd row of the wrist bones of the right hand are apparent. (D) The lateral (LL) projection showcases a complete dislocation of the II-V metacarpal bone in the dorsal direction with fragments of the metacarpal bones, along with subluxation of the I metacarpal bone dorsally.

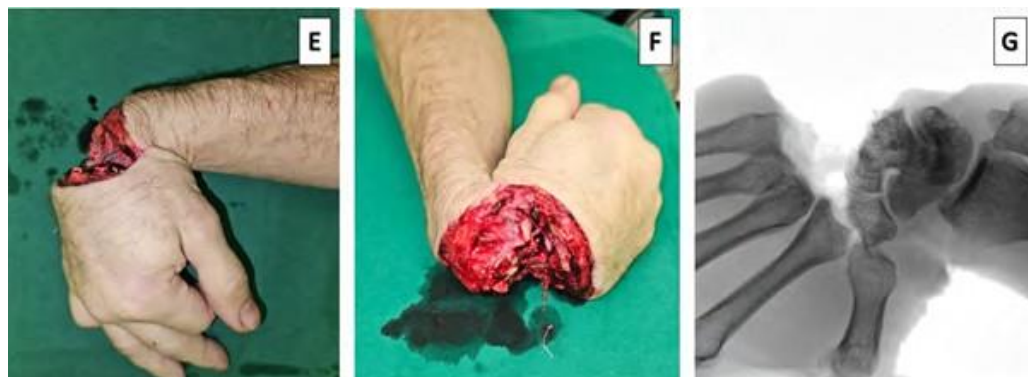

Figure 3: Intraoperative clinical images (E, F) and an intraoperative radiograph (G) collectively illustrate the impact of a traumatic injury, exposing a subtotal amputation of the right hand.

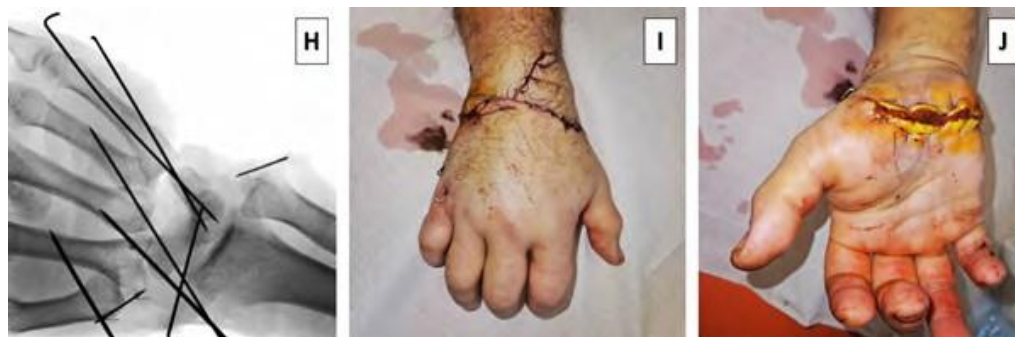

Figure 4: (H) Intraoperative radiograph demonstrates the implementation of Kirschner wires for securing MKK (I, II, III, IV, V) to the bones of the proximal carpal row. (I, J) Postoperative images reveal the right arm of the patient following surgery, just before the cast is applied for immobilization.

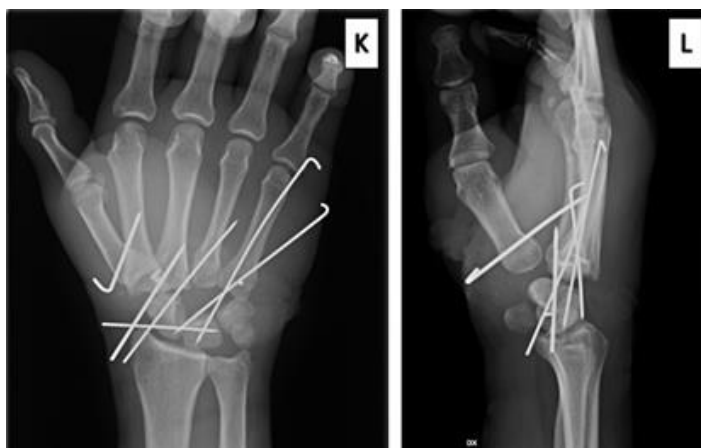


Figure 5: Postoperative radiographs reveal the successful fixation of MKK I, II, III, IV, and V using Kirschner wires, as depicted in (K) the PA projection and (L) the lateral projection.

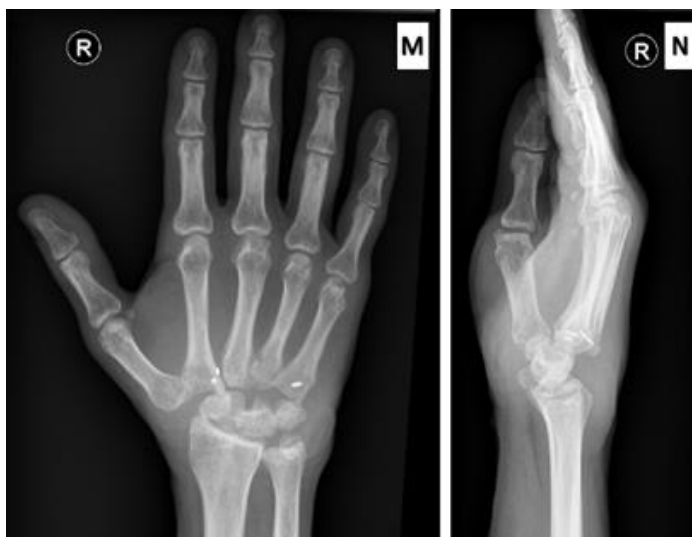

Figure 6: Six months post-surgery showcasing patients wrist (M) the PA projection and (N) the lateral projection.

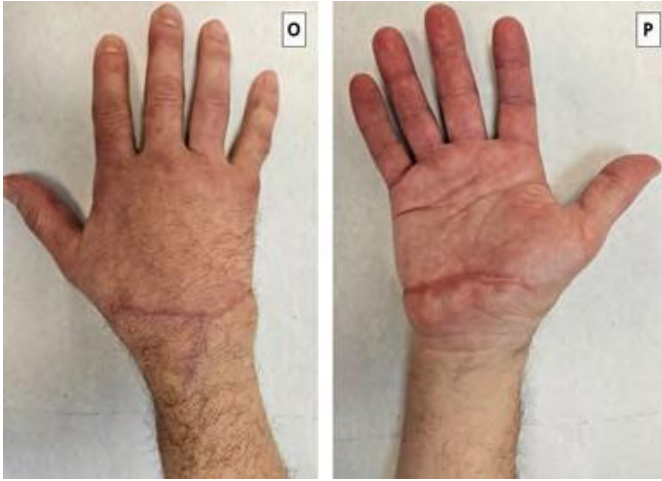

Figure 7: Six months post distal carpectomy Dorsal surface (O) and palmar surface (P) of the patient's hand.

4. Discussion

This case report highlights a successful treatment for a patient with a subtotal amputation of the right hand.

Severe wrist trauma, particularly involving the distal carpal row, is exceedingly rare and scarcely documented in the existing literature. To our knowledge, there are only a few other publications on distal row carpectomy, with one specifically addressing trauma patient.

Brodbeck et al. detail a comparable case report, with a patient experiencing a very specific trauma - direct injury during a circular saw accident. It resulted in a full-thickness wound with comminuted fractures of the dorsal left wrist and severe destruction of the distal carpal row [1]. The report detailed a distal row carpectomy's positive outcome - 18 months later, the patient showed excellent wrist movement, experienced no pain, and resumed normal personal and professional activities without limitations.

5. Conclusions

To sum up, our case report affirms the efficacy of distal row carpectomy as a favorable surgical intervention for patients with specific injuries affecting the distal carpal bones and soft tissues.

References

1. Brodbeck R, Horch RE, Arkudas A. Distal Row Carpectomy A Possible Salvage Procedure of Severe Carpal Trauma. *Plastic and Reconstructive Surgery – Global Open*. 2015; 3: e480.
2. Ansari MT, Digge VK, Mahmood A. Giant Cell Tumor of Triquetrum: A Case Report with Literature Review. *Journal of Wrist Surgery*. 2020; 10: 158-63.
3. Cunha PR, Nunes J, Ribau M, Correia G, Barbosa TM, Correia C, et al. Treatment of Scaphoid Nonunion Advanced Collapse Stage III with Proximal Row Carpectomy and Resurfacing of Capitate with Pyrocarbon Implant - Results of 2-Year of Follow-Up. *Acta Scientific Orthopaedics*. 2022.

Ali MH, Rizzo M, Shin AY, Moran SL. Long-Term Outcomes of Proximal Row Carpectomy: A Minimum of 15-Year Follow-Up. *Hand (N Y)*. 2012; 7: 72-8.

5. Chim H, Moran SL. Long-Term Outcomes of Proximal Row Carpectomy: A Systematic Review of the Literature. *J Wrist Surg*. 2012; 1: 141-8.