

Male Breast Microcalcifications? A Diagnostic Dilemma Type of Manuscript: Case Report

Chotai Niketa*

Consultant Radiologist, RadLink Women Imaging Center, Visiting Consultant, Tan Tock Seng Hospital, Singapore

***Corresponding author:**

Chotai Niketa,
 Consultant Radiologist, RadLink Women Imaging
 Center, Visiting Consultant, Tan Tock Seng
 Hospital, 15-04, RadLink Women Imaging Center,
 The Paragon Medical center, 290 Orchard Road,
 238859, Singapore,
 E-mail: niketachotai@gmail.com
 Orcid ID: 0000-0003-4005-2123

Received: 17 Mar 2023

Accepted: 18 Apr 2023

Published: 27 Apr 2023

J Short Name: AJSCCR

Copyright:

©2023 Niketa Chotai, This is an open access article distributed under the terms of the Creative Commons Attribution License, which permits unrestricted use, distribution, and build upon your work non-commercially.

Citation:

Niketa Chotai. Male Breast Microcalcifications? A Diagnostic Dilemma Type of Manuscript: Case Report. *Ame J Surg Clin Case Rep.* 2023; 6(11): 1-3

Keywords:

Pigmentation; Retroareolar; Gynaecology

1. Abstract

A tattoo is defined as either accidental or incidental pigmentation of the skin [1]. With the worldwide increase in the incidence of skin tattooing phenomenon, it is important to note the diagnostic challenge it poses in day today clinical practice. It is imperative for the radiologist to be aware of the radiological appearances of tattoo and beware of the potentials diagnostic pitfalls. This case also illustrates the importance of good clinical history taking and examination as the corner stone for good clinical diagnosis.

2. Case Report

We present a case of a 64-year-old Chinese gentleman who presented to the gynaecology outpatient department with a painful right breast lump. Clinical impression was that of right gynecomastia. He was referred to radiology department for right breast ultrasound for further evaluation. The ultrasound revealed dense fibroglandular breast tissue in the right retroareolar region. No focal hypoechoic solid lesion, cyst or dilated duct was detected. No similar findings were demonstrated on the left side (Figure 1).

The findings were compatible with the clinical diagnosis of gynecomastia. Supplementary right breast mammogram in standard craniocaudal (CC) and mediolateral oblique (MLO) views (Figure 2) were performed that revealed right retroareolar breast tissue compatible with the gynecomastia. Additionally, there were extensive fine microcalcifications seen in the right breast (Figure 2), more so in the upper inner quadrant of the right breast. They appeared to be amorphous in morphology and segmental in distribution. Some fine microcalcifications were also seen in the skin and subcutaneous layer. The findings were considered suspicious.

At this point of time, clinical examination was performed by the reporting radiologist and it was noted that the patient had skin tattoo over inner breast region (Figure 3). The pattern and extent of the microcalcifications exactly followed the tattoo mark on the chest. It was felt that the microcalcifications were related to the tattoo. For further confirmation, the stereotactic pair mammogram in right MLO projection was performed and measurements revealed that most of these calcifications were 0.6 to 1.0 mm from the skin surface. This confirmed them to be related to the tattoo.

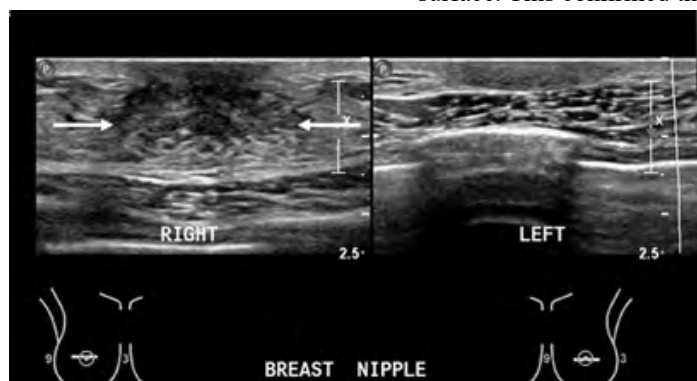


Figure 1: Ultrasound of bilateral breasts. Dense fibroglandular tissue (white arrows) is demonstrated in the right retroareolar region suggesting gynecomastia. Comparative left retroareolar region ultrasound image shows no similar tissue on the left side.

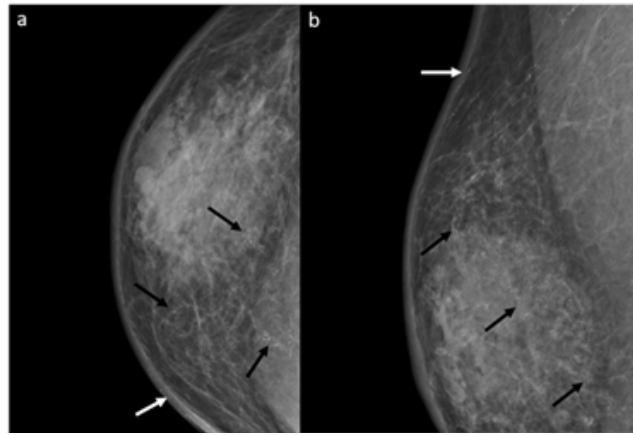


Figure 2: Right mammographic views in craniocaudal (a) and mediolateral oblique (b) views. There is presence of heterogeneously dense fibro-glandular parenchyma at the retroareolar region of the right breast, in keeping with gynecomastia. There are fine amorphous microcalcifications seen in the upper inner quadrant of the right breast (white arrows). Some fine microcalcifications are also seen in the skin and subcutaneous layer (black arrows). The microcalcifications are almost in segmental distribution making them concerning finding.

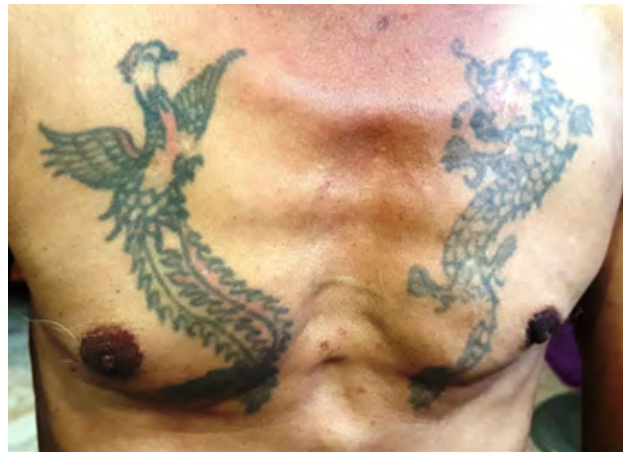

Figure 3: Clinical picture of the patient's chest demonstrating the skin tattoo over the upper inner breast region. The distribution of the tattoo closely follows the distribution of microcalcifications on the mammographic images.

3. Discussion

Skin tattoos are not to be confused with the well described “tattoo sign” in literature. First described in 1994 by Homer MJ et al [2], “tattoo sign” is a finding demonstrated in mammograms and refers to calcifications that maintain a fixed relationship to one another in repeat mammograms over a period of time. Skin tattoos on the other hand are deposits of pigment into the skin, usually iatrogenic [1, 3]. It consists of two main ingredients; a dye which is usually a heavy metal containing compound and determines the colour of the tattoo and a solvent [1]. Absence of any international standardization on use of dyes to make tattoos, makes it difficult to standardize the radiographic appearances.

There have been cases of tattoo pigment found in regional draining lymph nodes mimicking malignancy [1, 3, 5]. Weintraub et al reported a case of suspicious microcalcifications in the axillary node

on a screening mammogram that was later confirmed to be secondary to skin tattoo on fine needle aspiration cytology [4]. Core biopsies of these regional lymph nodes demonstrated the presence of tattoo pigment within. To our knowledge, this is the first case, where skin tattoo presented as concerning microcalcifications on mammogram in a male patient. An initial diagnostic dilemma and potential adverse intervention was prevented by diligent observation and reporting on part of the reporting radiologist.

In conclusion, skin tattoo is a potential cause of false-positive findings of microcalcifications on mammography and should be considered when there is discordance in the clinical and radiological findings. This case also goes on to illustrate that we as clinical radiologists need to perform a thorough clinical examination when needed to prevent invasive procedures like core biopsy or surgery and potential adverse outcome.

References

1. Matsika A, Srinivasan B, Gray JM, Galbraith CR. Tattoo pigment in axillary lymph node mimicking calcification of breast cancer. Case Reports. 2013; 2013: bcr2013200284.
2. Homer MJ, D'Orsi CJ, Sitzman SB. Dermal calcifications in fixed orientation: the tattoo sign. Radiology. 1994; 192(1): 161-3.
3. Mentrikoski MJ, Rochman CM, Atkins KA. Tattoo ink within lymph nodes: A possible clinical mimicker of abnormal calcifications. The Breast Journal. 2014; 20(3): 314-5.
4. Weintraub K. Tattoo Pigment in Fine-Needle Aspiration Cytology of an Axillary Lymph Node. American Journal of Clinical Pathology. 2014; 142(suppl_1): A057.
5. Honegger MM, Hesseltine SM, Gross JD, Singer C, Cohen JM. Tattoo pigment mimicking axillary lymph node calcifications on mammography. American Journal of Roentgenology. 2004; 183(3): 831-2.