

Thoughts and Suggestions for Lower Alveolar Nerve Injury Caused by Tooth Extraction on the Lower Left 8th Tooth: A Case Report

Chen J^{1*}, Florenly² and Liu C³

¹Major of Clinical medicine, Specialization of Dental Medicine, Faculty of Medicine, Dentistry, and Health Science, Universitas Prima Indonesia, JL.Belanga No.1 Simp.JL Ayahanda Medan, Indonesia, 20118.

²Major of Clinical medicine, Specialization of Dental Medicine, Faculty of Medicine, Dentistry, and Health Science, Universitas Prima Indonesia, JL.Belanga No.1 Simp.JL Ayahanda Medan, Indonesia, 20118, ORCID ID: 0000-0002-6326-3751, Scopus ID: 57191633272.

³Major of Clinical medicine, Specialization of Surgery Faculty of Medicine, Dentistry, and Health Science, Universitas Prima Indonesia, JL.Belanga No.1 Simp.JL Ayahanda Medan, Indonesia, 20118, ORCID: 0000000160660340

*Corresponding author:

Chen Jun,
Major of Clinical medicine, Specialization of
Dental Medicine, Faculty of Medicine, Dentistry,
and Health Science, Universitas Prima Indonesia,
JL.Belanga No.1 Simp.JL Ayahanda Medan,
Indonesia, 20118, E-mail: 18871478098@163.com

Received: 25 Dec 2022

Accepted: 07 Feb 2023

Published: 15 Feb 2023

J Short Name: AJSCCR

Copyright:

©2023 Chen J, This is an open access article distributed under the terms of the Creative Commons Attribution License, which permits unrestricted use, distribution, and build upon your work non-commercially.

Citation:

Chen J. Thoughts and Suggestions for Lower Alveolar Nerve Injury Caused by Tooth Extraction on the Lower Left 8th Tooth: A Case Report. *Ame J Surg Clin Case Rep.* 2023; 6(6): 1-5

Keywords:

Teeth; Inferior alveolar nerve; Iatrogenic injury; Tooth extraction, injury; Wisdom teeth

1. Abstract

1.1. Background: Among the injury mechanisms of multiple traumas, iatrogenic injuries and non-medical injuries are included, among which iatrogenic injuries are still inevitable. Aerginal injuries can be divided into beneficial iatrogenic injuries and adverse iatrogenic injuries. Favorable iatrogenic injury refers to tissue and organ damage caused by the treatment of the disease. Unfavorable iatrogenic injury refers to tissue and organ damage caused unintentionally or reluctantly in the process of treating the disease. At present, dentists around the world are very mature for tooth extraction technology, but it is inevitable that adverse hospital injuries sometimes occur, including blood vessels, nerves, bone and other injuries.

1.2. Research Methods: explore the clinical manifestations, diagnosis and treatment of nerve injury after tooth extraction through deep learning and research; summarize experience, learn lessons, and reduce the incidence of nerve injury. This study is a case of inferior alveolar nerve injury caused by A8B8C8D8 tooth extraction in a 25-year-old young female patient. Let's study and lessons learned together.

1.3. Objective: To study the manifestations, diagnosis and treatment of inferior alveolar nerve injury after tooth extraction. We summarize and grasp the indications and contraindications of tooth extraction, and operate carefully in tooth extraction, and actively treat and treat them when inevitably lead to injury to blood vessels, nerves and bones.

1.4. Study Results and Significance: Young 25-year-old female

patients underwent A8B8C8D8 tooth extraction, resulting in inferior alveolar nerve injury, numbness and discomfort in the mandibular area and teeth, and weak bite. Later, symptomatic treatment, nutritional nerves, rehabilitation function exercise and other treatments were improved and discharged from the hospital. For every dentist, you must strictly grasp the indications and contraindications of tooth extraction, operate softly and avoid violence. When intraoperative complications cannot be avoided, blood vessel, nerve and bone damage can be treated in time to reduce sequelae.

2. Introduction

Tooth extraction is the most common, basic and widely used therapeutic operation in the field of oral and maxillofacial surgery, and it is also a basic treatment method that stomatologists must master [1]. Traditional tooth extraction, especially irregular operation or improper preoperative, intraoperative and postoperative treatment, is easy to cause local vascular, neurological and bone damage, which is manifested in complications such as bleeding, infection, tooth fracture, tooth crushing and displacement, and even jaw fracture or temporomandibular joint injury. In fact, iatrogenic damage may occur during tooth extraction, and peripheral nerve, blood vessels and tissue injuries that are unintentionally or reluctantly caused in the process of tooth extraction to treat diseases. Clinically, when the mandibular wisdom tooth is imprisonant and the tooth is located at the end of the mandibular dentary, it is also the latest tooth erupted from the human body's permanent teeth. Due to the increasing finer of human food, the chewing stimulation required for the normal development of the jaw gradually decreases,

leading to the degeneration of the jaw, resulting in the length of the jawbone and the length of the dentary. Therefore, when the age of the germination of the lower hectare wisdom teeth is reached, its proper position has been occupied by other teeth, which objectively causes the obstruction of the germination of the mandibular wisdom teeth. Anatomically, in the jaw bone of the deep surface of the tooth, there is a inferior alveolar nerve passing through the nerve, which is the sensory nerve that governs the heel, mucous membrane and whiskers of one side of the mandibular teeth. Because the location of the inferior alveolar nerve is very close to the position of the obstructive mandibular wisdom tooth, especially the low-level impedance of the mandibular wisdom tooth, which is completely ambushed, it is almost separated from the nerves by only a thin bone plate, as shown in Figure 1. When it is much more difficult to pull out this kind of tooth than other teeth, you need to cut the covered teeth, chisel the bones on the ambush teeth, and sometimes split the ambush teeth into a few pieces to pull them out. Therefore, the obstructive teeth of mandibular wisdom teeth take a long time to remove bones and split teeth. During the operation, it is very likely to hurt the adjacent inferior alveolar nerve, resulting in numbness, sensory abnormalities, and weak bite of the lower lip (including simultaneous mandibular bran) after the operation. Generally speaking, simple nerve injury can recover from lower lip numbness about 3 months after taking conventional neurotrophic drugs, and some may be extended to 6 months [2]. A case report inferior alveolar nerve injury caused by tooth extraction of lower left No. 8 was reported as follows.

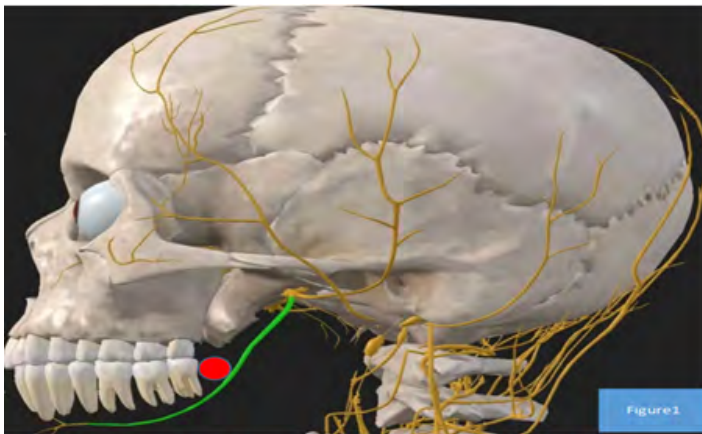


Figure 1: Expression is the relationship between the left mandibular wisdom tooth and the anatomy of the left lower alveolar nerve.

3. Clinical Data

3.1 Disease History Introduction

The patient, female, 25 years old, was admitted to our hospital for “discovering a left mandibular mass for 6+ months”. There is nothing special in the past. Specialized examination: the patient’s face type is symmetrical, the expression is cooperative, the opening type is acceptable, the opening is three fingers, the bilateral temporomandibular joint activity is consistent, and there is no tenderness. It can be seen that oral hygiene is good in the mouth,

low resistance in the A8B8 cheek, the near and middle part of C8 germinates, and the far and middle part of the gum flaps are covered. D67 corresponds to the lateral vestibular groove of the cheek, there is no pain, no germination of D8, and there is no redness, swelling on the surface and surrounding gums: D7 is not loose, percussion pain (-); there is no redness and swelling of the mouth of the bilateral parotid glands and subcollar gland catheters, and the secretions are clear: the superficial surface of the bilateral collar and neck are not beaten and obvious superficial swollen lymph nodes.

3.2. Preoperative Evaluation and Discussion

Patient’s condition and feasibility assessment Patient’s blood routine: WBC $3.11 \times 10^9/L$, hemoglobin 107g/L, platelet $267.0 \times 10^9/L$, Anti-HBS positive, HIV-Ab negative, TP-Ab-negative, A-type RH positive (+), chest CT scan does not see exact lesions, electrocardiogram shows sinus rhythm. Oral X-ray examination: left mandibular 8 obstructive teeth, see Figure 2. To sum up, the above patients have surgical indications and no absolute surgical contraindications. After knowing it, the patient signs and agrees to the surgical treatment.

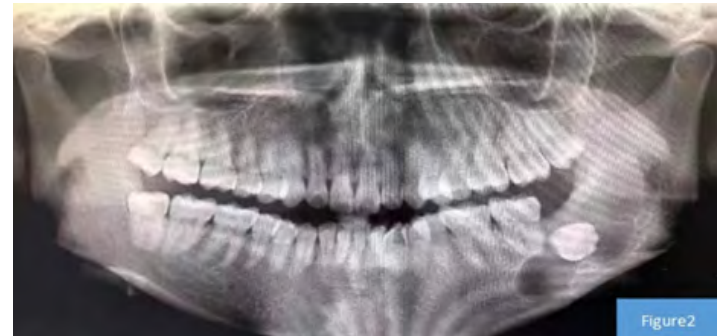


Figure 2: Expression is the result of the patient’s preoperative oral X-ray examination.

4. Surgical Process: Left Mandibular Cyst Window Decompression + A8B8C8D8 Obstructive Tooth Extraction

4.1. Position

The patient takes a flat position.

4.2. Disinfection Method

After the patient’s general anesthesia takes effect, routine disinfection and application.

4.3. Incision

Incision one, in the distance of the side can be used as a day, and silver micro-incision, solid “savement gum, shape Jiang Ao’ao one-angle incision; incision 2: make a angular incision on the C6 cheek side, C8 crown far middle gum; incision gum to make a angular incision; incision 3: make a angular incision on the B7 crown cheek side gum; incision 4: make a angular incision on the gingival of A7 crown cheek side gum.

4.4. Surgical Steps

Apply aureomycin eye ointment to the lips and corners of the

mouth, open the left corner, reveal the operation area, according to the incision one design, open the mucus microdynamic system to remove the lesion membrane directly to the bone surface, the periosteum peeler opens the mucosal flap, see that there is a thin cortical bone in the crown of the cyst, the bone microdynamic system removes the lesion thin cortical bone, exposes the cyst cavity after removing the mandibular cortex, explore the swelling range, the location of D8 in the cystic cavity and its relationship with D7, see the brown thin cortical bone, remove the chin bone cortex, exposing the cyst cavity after removing the swelling the swelling range and After trimming the surrounding sharp bone, the physiological saline is repeatedly rinsed, trimming the gum flap to form an drainage outlet with a diameter of about 2cm, trimming the local gums to form any flap, suture the sac wall with the gingival mucosa into a pocket shape, and place iodine imitation gauze in the sac cavity. The second incision is designed on the side of the C6 cheek side and the far middle gum of the C8 crown to make a angular incision, and the incision membrane reaches the bone surface; peel and open the gum mucosus flap along the bone surface to reveal the C8 crown cheek side, far and medium bone, use the bone microdynamic system to cooperate with bone splitting to remove the C8 corresponding crown, cheek side and far and medium bone cortex, continue bone splitting to remove the resistance of the C8 crown cheek and far and medium bone, and expose the maximum circumference diameter of the C8 crown; after the crown is straightened out of C8. After checking the C8 tooth body tissue integrity: scratching the C8 alveolar nest extracting inflammatory granulation tissue to prevent active bleeding, trim and reset the alveolar bone Along the incision III, a angular incision is made on the side of the B7 crown cheek gingival, and the mucosa is cut straight to the bone surface; the gingival mucosal flap is peeled and opened along the bone surface to reveal the cheek side, far and medium bone of the B8 crown, expose the maximum u-reset alveolar bone of the B8 crown, trimming and reset the impeded gingival mucosal flap so that it can absorb suture intermittent suture incision after alignment. The A8 was pulled out in the same way, and after inspection, A7B7C7D7 was not loose. Gauze compresses the A7B8C8D8 tooth extraction area to stop bleeding. The extracted A8B8C8D8 dental tissue is handed over to the family for inspection and disposed of it as medical waste. The operation went smoothly. After the operation, the patient woke up and pulled out the resuscitation room and closely observed the patient and returned to the ward.

4.5. Instructions on Changing the Surgical Plan

None.

4.6. In-Operative Bleeding, Blood Transfusion and Reaction

20ml of bleeding.

4.7. Unexpected Operation

None.

4.8. Surgical Anesthesia

Good.

4.9. Inventory of Surgical Instruments and Dressings Before Suture Incision

None. Special replacements, equipment, etc. used in the operation: Yes; two sutures can be absorbed; one pack of iodine imitation yarn.

5. Clinical Manifestations and Histopathological Results of Patients after Surgery

When the patient underwent “left mandibular cyst window decompression + A8B8C8D8 impregnated tooth extraction”, the patient showed numbness and discomfort in the left mandibular area and teeth, as well as weak occlusal, as shown in Figure 3. After the operation, hemorrhage and swelling were relieved; methylcobalamin was taken orally to improve the numbness symptoms after inferior alveolar nerve injury in March [3]. After the operation, the tissue was seen with the naked eye: the left mandibular cyst, a gray-white gray-brown cystic wall-like tissue, a volume of 1.5cm*1.2cm*0.3cm, the content of the capsule was lost, the inner and outer wall of the capsule was smooth, and the thickness of the cyst wall was 0.1-0.2cm. The pathological result is (left mandibular cyst): it conforms to the dentogenic keratification cyst, see Figure 4.

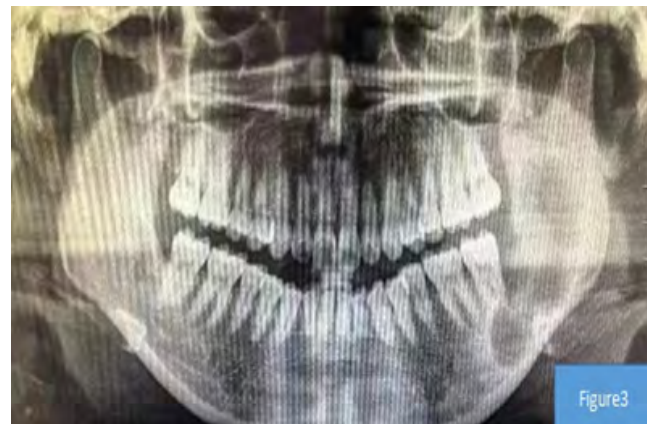

Figure 3: The expression is a picture of the patient's postoperative oral X-ray examination results.

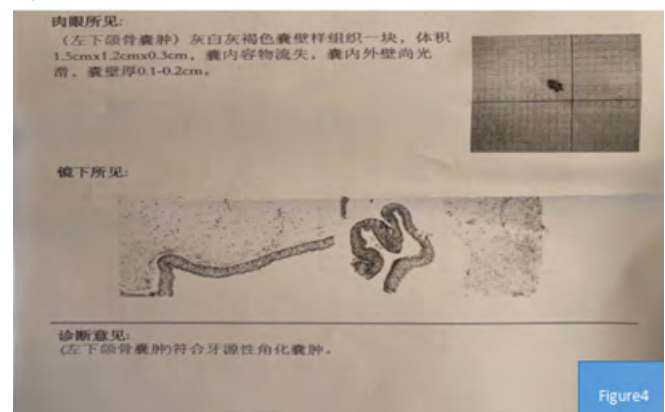


Figure 4: Expression is the histopathological examination result of the patient's removal of A8B8C8D8 obstructive teeth.

6. Discussion

6.1. Anatomical Relationship Around the Inferior Alveolar Nerve

Wisdom teeth are the third molar teeth in the human oral alveolar bone, which happens to be the eighth tooth [4]. The inferior alveolar nerve is a branch of the mandibular nerve, which is shaped in the mandibular tube with a fine diameter [5]. The cross section of the mandibular canal is irregularly elliptical and moves from the chin hole from the side of the tongue to the cheek. The bone gradually thins and there is no complete periosteum around the chin hole. The distance between the mandibular tube from each root (i.e. the sole of the alveolar) is 12.57 mm of the incision, 10.06 mm of the lateral incision, 9.28 mm of the fangs, 8.04 mm of the second front molar, and 7.59 mm of the second molar. The outer part of the lower alveolar nerve tube is 25.93 mm long, the inner part of the tube is 67.97 mm long, and the human mandibular hole is 2.58 mm wide and 1.86 mm thick. In the wisdom tooth extraction operation, extracting according to the correct anatomical position and depth can avoid damage to the inferior alveolar nerve.

6.2. Clinical Manifestations, Body Examination, Auxiliary Examination and Treatment of Inferior Alveolar Nerve Injury

Patients with sensory abnormalities, uncoordinated movement and other comprehensive clinical manifestations after tooth extraction causes inferior alveolar nerve injury. During the physical examination, it can be found that the bite is weak on the side of the inferior alveolar nerve injury. Auxiliary examination can be used with CBCT and MSCT to evaluate the inferior alveolar nerve injury after surgery. Kim et al. [7] also focused on the overlap of roots and neural tubes in panoramic films. By exploring the relationship between the imaging manifestations of panoramic film and CBCT and the symptoms of nerve injury after tooth extraction, the researchers found that the ability of CBCT to reduce inferior alveolar nerve injury is not statistically significant. If the panoramic film or CBCT indicates that the diameter of the neural tube changes through the root area, it is more likely that the alveolar nerve will be damaged during the operation. Nakagawa et al. [8] believe that the panoramic film in patients shows the presence of bone white lines, and the probability of damaging the alveolar nerve during tooth extraction is higher. This research result provides another reference standard for clinicians to read panoramic films before

surgery, enriches the information provided by panoramic films, and improves the accuracy of panoramic films in judging the adjacent relationship between the two. Therefore, CBCT and MSCT are important for judging the injury of inferior alveolar injury after tooth extraction. Combined with the patient's surgical history of extracting wisdom teeth, the patient showed abnormal numbness sensation after the operation, and the bite was weak during the physical examination, which assisted the examination and supported the diagnosis. After the operation, methylcobalamin nutritional neurotherapy was given for 3 months, and regular rehabilitation exercise was exercise. Patients can recover in the later stage.

6.3. Thinking and Suggestions

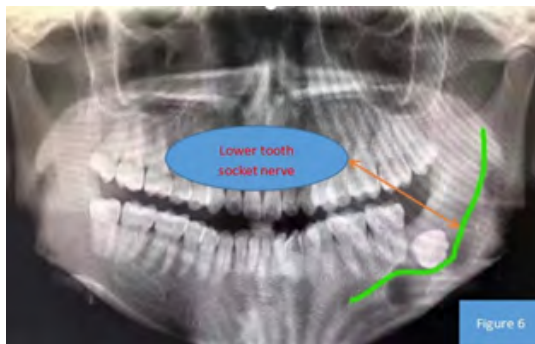
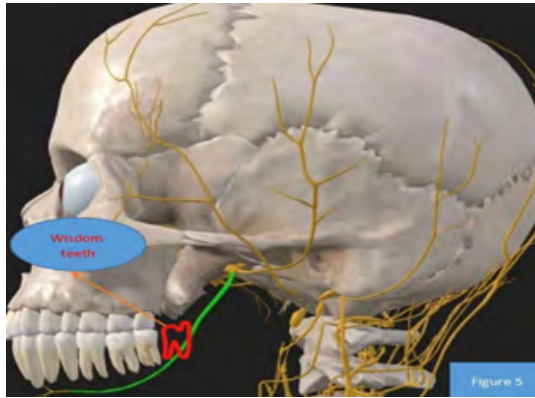
Through this case, we can learn the schematic diagram of the anatomy relationship between the left wisdom tooth and the surrounding tissue of the patient and the travel of the left inferior alveolar nerve of the left X-rays before surgery, as shown in Figures 5 and 6. Based on the above research, we can conclude that as professional dentists, we must master the indications and contraindications of tooth extraction [9], and the auxiliary examination needs to be improved before the operation to assess the patient's health. If the patient evaluates that the patient cannot operate for the time being, he can first give comprehensive treatment such as anti-infection and anti-swelling, and wait for the patient's overall health condition to be good before choosing surgical treatment. Doctors should avoid violent operation during surgery, if violent operation can lead to nerve, blood vessel, mandibular fractures, etc. [10]. If the inferior alveolar nerve must be damaged during the operation when the condition requires, the patient should be informed before the operation that the inferior alveolar nerve may be damaged during the operation, what treatment should be given after the operation, and follow-up later. Avoid medical disputes.

7. Author's Statement

This study is approved by the author, and its case data is used for academic research. The research data is provided by Jun Chen ; his email address is 18871478098@163.com, and all authors have no conflicts of interest.

Jun Chen : Write a paper.

Florenly(MD, PHD)and Chao Liu: Statistics, review essays and paper drawing.



Figures 5 and 6: This study studied the schematic diagram of the anatomy relationship between wisdom teeth and peripheral tissues and the travel of X-ray nerves before surgery.

References

1. Hu Kaijin waited. A new concept of modern standard tooth extraction [J]. Chinese Journal of Practical Stomatology. 2010; 10: 577-81.
2. Wangjun Y, etc. Common dental extraction complications and treatments [J]. Chinese Medicine Guide. 2011; 9(7): 44-5.
3. Huan X, Yu L, Yang S, Haizhen W, etc. Observation on the preventive effect of methylcobalamin on related symptoms after lower alveolar nerve vascular bundle injury caused by tooth extraction [J]. Anhui Medicine. 2017; 7: 1322-4.
4. Wei L, Jun G, Jun J, etc. False coronitis of mandibular wisdom teeth was misdiagnosed in 7 cases [J]. Journal of the Third Military Medical University. 2002; 24: 322-5.
5. Wei D, Daiying H, Songling C, etc. Magnetic resonance imaging shows the accuracy of the geometry of the lower alveolar nerve [J]. China Organizational Engineering Research. 2014; 24: 3840-4.
6. Wenhao F, Nengrui Y, Rongming J, long HH, Xinnan Z, Yunjie S, etc. Applied anatomy of mandibular tube and lower alveolar nerve [J]. Journal of Anatomy. 2014; 37: 75-8.
7. Kim HG, Lee JH. Analysis and evaluation of relative position so f mandibular third molar and mandibular canal impacts [J]. JKorean Assoc Oral Maxill of ac Surg. 2014; 40(6): 278-84.
8. Nakagawa Y, Ishi H, Nomura Y, et al. Third molar position:reliability of pan or a microradiography[J]. J Oral M ax ill of ac Surg. 2007; 65(7): 1303-8.

9. Songlin M, Yan L, Xiaofeng W. Indications, contraindications and preoperative preparation for tooth extraction in elderly patients with cardiovascular disease [J]. Heilongjiang Medical Science. 2001; 2: 117.
10. Yongqing MA, Miaomiao YANG. Effect of Colloidal Silver Gelatin Sponge on Prevention of Complications after Tooth Extraction in Diabetic Patients [J]. Journal of Oral Science Research. 2020; 36(12): 1168-71.