

Thoughts and Suggestions of Grassroots Doctors (Gastroenterologists and General Practitioners) of Lower Gastrointestinal Bleeding Caused by Long-Term Use of Non-Steroidal Anti-Inflammatory Drugs and a Case Report

Shen J¹, Liu C^{2*} and He L³

¹Department of Gastroenterology, Third People's Hospital of Yuhang District, China

²Department of General Surgery(Direction of Gastrointestinal Tumor), Medicine Faculty of Universitas Prima Indonesia, Indonesia

³Department of Osteology, Second People's Hospital of Yuhang District, China

*Corresponding author:

Chao Liu,

Department of General Surgery(Direction of gastrointestinal tumor), Medicine Faculty of Universitas Prima Indonesia, medan 20112, North Sumatra,

Indonesia, E-mail:liuchao1838044@163.com,

sjj635436653@163.com and

h18968087863@163.com

Chao Liu: ORCID: 0000000160660340

Jianjun Shen ORCID: 0000000263638453

Lijiang He ORCID: 0000000275732404

Received: 25 Dec 2022

Accepted: 06 Feb 2023

Published: 15 Feb 2023

J Short Name: AJSCCR

Copyright:

©2023 Liu C, This is an open access article distributed under the terms of the Creative Commons Attribution License, which permits unrestricted use, distribution, and build upon your work non-commercially.

Citation:

Liu C. Thoughts and Suggestions of Grassroots Doctors (Gastroenterologists and General Practitioners) of Lower Gastrointestinal Bleeding Caused by Long-Term Use of Non-Steroidal Anti-Inflammatory Drugs and a Case Report. *Ame J Surg Clin Case Rep.* 2023; 6(6): 1-4

Abbreviations:

NSAIDs: Non-Steroidal Anti-Inflammatory Drugs;

PG: Prostaglandin, COX1: Cyclooxygenase1; COX2:

Cyclooxygenase2; PGI2: Prostaglandin2

Keywords:

Non-steroidal anti-inflammatory drugs; NSAIDs;

Colon ulcer; Lower gastrointestinal bleeding

1. Abstract

1.1. Introduction: Non-Steroidal Anti-Inflammatory Drugs (NSAIDs) cause many side effects in digestive tract, especially in upper digestive tract, but rarely in lower digestive tract.

Patient concerns The patient, a 40-year-old male, the patient developed abdominal pain without obvious inducement, mainly paroxysmal dull pain in the left lower abdomen, and relieving bright red bloody stool for 4 times, each time with a volume of about 50-100ml, without black stool, mucous stool, diarrhea and fever.

1.2. Diagnosis: Gastroscopy showed chronic non-atrophic gastritis, and Colonoscopy showed multiple strip ulcers of sigmoid colon, with a size of about 0.2*1.0cm, covered with white fur, and normal mucosa between ulcers. Endoscopy showed multiple ulcers of sigmoid colon, and pathology showed acute and chronic inflammation, erosion and ulcer formation of colon mucosa. Therefore, the diagnosis of multiple colon ulcers is considered.

1.3. Interventions: Stop taking NSAIDs, use hemostatic drugs and treat them symptomatically.

1.4. Outcomes: The patient's lower gastrointestinal bleeding stopped and abdominal pain disappeared. Colonoscopy showed

that colon ulcer healed.

1.5. Conclusion: Grass-roots gastroenterologists should pay attention to patients who use NSAIDs for a long time, because these drugs can cause lower gastrointestinal bleeding. Grass-roots gastrointestinal physicians and grass-roots general practitioners manage and educate patients together, which is beneficial to improve patient satisfaction.

2. Introduction

Non-Steroidal Anti-Inflammatory Drugs (NSAIDs) are common drugs in clinical treatment, has obvious efficacy in antipyretic, analgesic and anti-inflammatory aspects, It is also a drug with more side effects. However, for a long time, the medical technology level in some grass-roots hospitals is limited, and doctors' cognitive ability of drug indications is insufficient. NSAIDs can-not be used correctly and effectively, which leads to some side effects of digestive tract [1]. The mucosal injury of stomach and duodenum in upper digestive tract is common, while the injury of lower digestive tract is very rare. Now, a case of colon ulcer with lower gastrointestinal bleeding caused by NSAIDs in primary hospital is reported as follows.

3. Clinical Data

The patient, a 40-year-old male, was admitted to hospital on May 28, 2022 because of “abdominal pain accompanied by relieving bright red bloody stool for half a day”. Half a day ago, the patient developed abdominal pain without obvious inducement, mainly paroxysmal dull pain in the left lower abdomen, and relieving bright red bloody stool for 4 times, each time with a volume of about 50-100ml, without black stool, mucous stool, diarrhea and fever. He had a history of gout for 2 years and went to the local community health service center for a long time. In recent 3 months, the patient took diclofenac sodium capsules and profen codeine sustained-release tablets irregularly. Admission physical examination: the general condition is OK, the blood pressure is 130/76 mmhg, the mind is clear, the spirit is OK, there is no anemia, the superficial lymph nodes are not touched, the cardiopulmonary physical examination is no abnormality, the abdomen is soft, there is no obvious tenderness and rebound pain, the bowel sounds are active, and there is no edema in both lower limbs. Auxiliary examination: gastroscopy showed chronic non-atrophic gastritis; Colonoscopy showed multiple strip ulcers of sigmoid colon, with a size of about 0.2*1.0cm, covered with white fur, and normal mucosa between ulcers. Endoscopy showed multiple ulcers of sigmoid colon, and pathology showed acute and chronic inflammation, erosion and ulcer formation of colon mucosa (Figure 1). Immediately after admission, NSAIDs drugs were stopped, and symptomatic treatment such as hemostasis, rehydration and intestinal probiotics were given. After admission for 24 hours, the patient had no symptoms such as bloody stool and abdominal pain. One month after treatment, colonoscopy reexamined that the colon ulcer had healed, and local stripe mucosa congestion was seen (Figure 2). Three months after treatment, colonoscopy showed no abnormality in colonic mucosa (Figure 3). After being treated by digestive physicians, patients are recommended to the general practitioners in their communities for full management, so as to understand the changes of patients' conditions, introduction of medication, health education, and make an appointment for colonoscopy at the digestive physicians in the later period. Patients are very satisfied with this medical model and medical service.

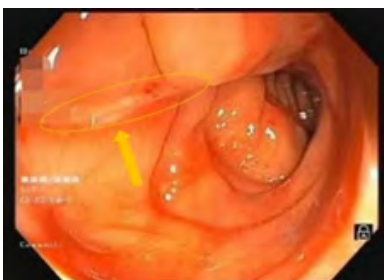

Figure 1: The first colonoscopy after the onset of the disease.

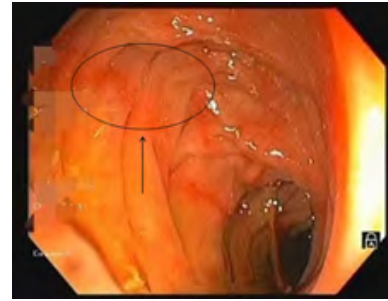


Figure 2: the endoscopic appearance after 1 month of treatment.

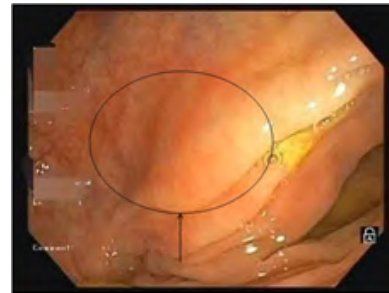

Figure 3: The colonoscopic and endoscopic manifestations after 3 months of treatment.

4. Discussion

This is a case of multiple colonic ulcers complicated with lower gastrointestinal bleeding. The patient had no intestinal diseases in the past, no family history of gastrointestinal tumors, and developed during taking NSAIDs. Colonoscopy showed multiple colonic ulcers, and the mucosa between ulcers was normal. Pathology showed acute and chronic mucosal inflammation, erosion and ulcer formation. After stopping NSAIDs, one month later, colonoscopy showed the ulcers healed. Therefore, this case of colonic ulcer complicated with lower gastrointestinal bleeding was considered to be caused by NSAIDs. NSAIDs mainly affect arachidonic acid metabolism by inhibiting Cyclooxygenase (COX), thereby inhibiting Prostaglandin (PG) synthesis. Achieve anti-inflammatory, analgesic, antipyretic and other effects, COX has two isomers, COX-1 and COX-2, Where COX-1 is a structural enzyme, It is expressed in most tissues, After being activated, it can synthesize PGI₂ and play a protective role in gastric mucosa. COX-2 is an inducing enzyme, which exists in inflammatory sites and is activated under the induction of inflammatory factors, which leads to the release of inflammatory mediators and induces pain and inflammatory reactions. Therefore, selective inhibition of COX-1 injury gastric mucosal, while selective inhibition of COX-2 activity can play antipyretic, analgesic and anti-inflammatory effects [2].

The application of NSAIDs, a new agent, reduces the injury to upper digestive tract, but the colon injury increases gradually. The mechanism of causing or aggravating colon injury may be related to the following factors: the direct stimulation of NSAIDs on colon mucosa leads to mucosal injury. NSAIDs inhibit the synthesis of prostaglandins: Prostaglandins can maintain cell vitality. If their synthesis is inhibited, colon cells can be damaged. Endogenous

prostaglandins can regulate the synthesis of inflammatory substances and inhibit the infiltration of neutrophils. Therefore, the inhibition of prostaglandins synthesis is beneficial to the local infiltration of neutrophils, resulting in mucosal injury. The production of leukotrienes inflammatory substances increased. NSAIDs promoted the production of leukotrienes and other inflammatory substances by inhibiting cyclooxygenase and then metabolizing lipoxygenase, which played an important role in the occurrence of inflammatory bowel disease [3].

5. Prevention and Suggestions

With the wide application of NSAIDs, its gastrointestinal side effects are increasing day by day, especially in intestinal injury. How to reduce or avoid the intestinal side effects of NSAIDs should be as follows: Strengthen the study of standardized medication for gastroenterologists and strengthen the medication guidance for patients. Try to use drugs that selectively inhibit COX-2 to retain the therapeutic effect and reduce side effects. High-risk groups should try not to use NSAIDs, reduce the dose when they must use it, avoid the combined use of NSAIDs [4], and give intestinal mucosal protective agents and intestinal microecological preparations. Once gastrointestinal side effects, especially intestinal injury, occur during the use of NSAIDs, the medication should be stopped immediately to prevent serious complications and life-threatening, especially for the elderly and patients who need to take it for a long time [5]. When the disease is serious or bleeding, perforation or canceration, the gastrointestinal tumor surgeon should treat it in time.

General practitioners need to know the disease diagnosis, treatment opinions, the patient's condition changes and care throughout the whole process, and regularly know the patient's condition and medication. Give full play to the role of health education. Such patients need gastroenterologists and general practitioners to work together to manage patients. Give full play to the specialty of specialists and reflect the value of general practitioners.

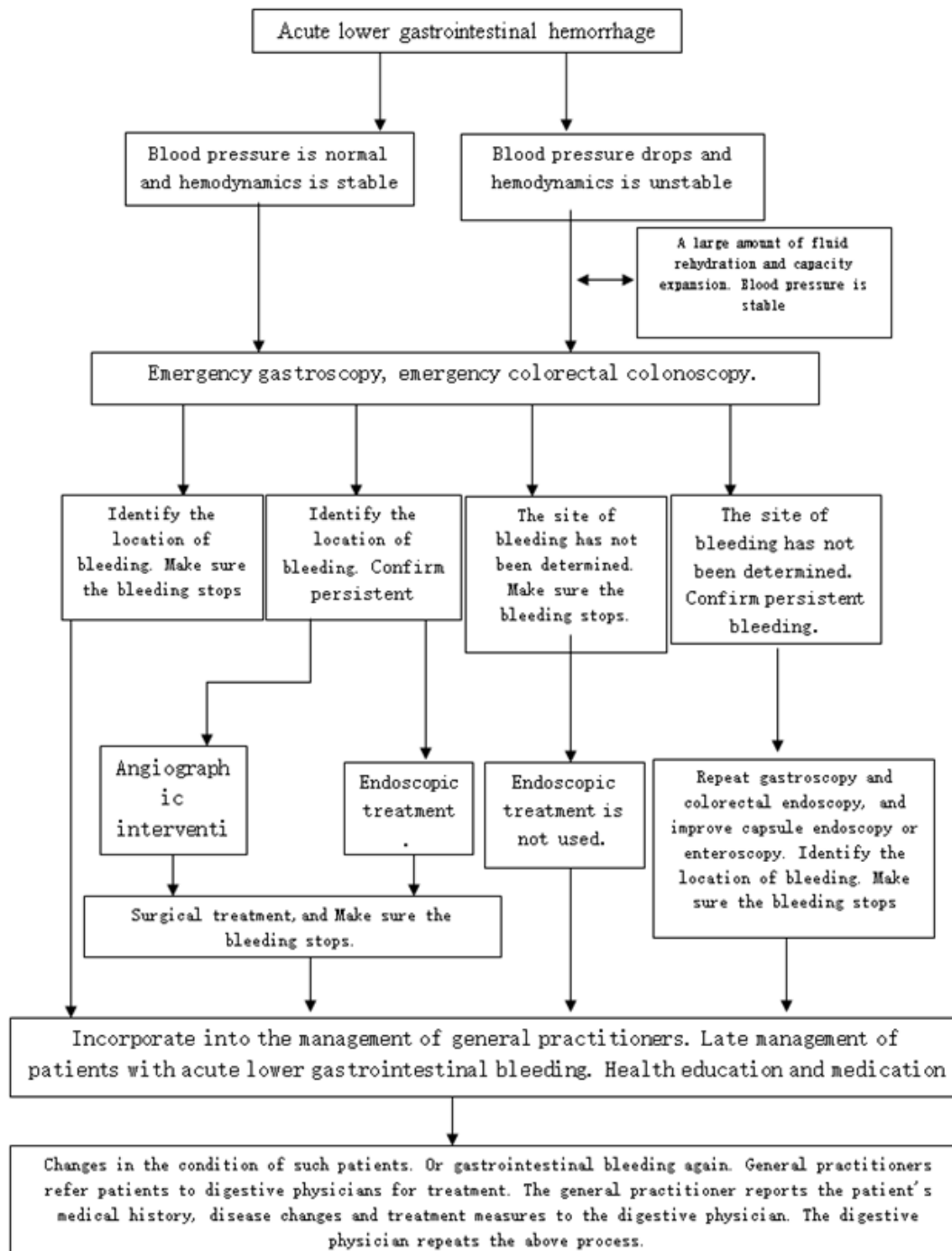
6. Medication management and monitoring of NSAIDs in grass-roots hospitals

Gastroenterologists should regularly train general practitioners, including medication safety and indications. Gastroenterologists and general practitioners should inform patients of the efficacy and risks before medication, after weighing the pros and cons, choose the appropriate NSAIDs, and give pre-medication education to patients, including the medication time, dosage, course of treatment, side effects, etc. Doctors should regularly follow up patients who are using NSAIDs to know the changes of patients' conditions and gastrointestinal side effects in time. It is beneficial to adjust the treatment plan in time. For patients with gastrointestinal side effects after medication, doctors should actively find out the reasons and take measures. Serious gastrointestinal side effects: bleeding and perforation are reduced by such treatment measures. Grass-roots hospital is a comprehensive medical group, which needs specialists to give full play to their specialties and take advantage of the convenience of general practitioners. Specialists and general practitioners play an important role in primary health care and can provide better medical services for primary patients. From the analysis of this case, we can understand the different values and meanings of specialists and general practitioners. They perform their duties, seamlessly connect the diagnosis and treatment of patients, and apply integrated and continuous medical services to the whole process of patient management, health education and disease treatment. Therefore, this study has the significance of reference and publicity. Finally, Flow chart of treatment of lower gastrointestinal bleeding by primary gastroenterologists and general practitioners (Supplemental Digital Content 1).

7. Acknowledgments

The authors report no conflicts of interest. There is no financial support for this study. The patient has provided informed consent for publication of the case.

Flow Chart:



Supplemental Digital Content 1: Treatment flow of lower gastrointestinal bleeding by primary gastroenterologists and general practitioners.

References

1. Sulan R, Xiaoyun L. Analysis of antibiotics and NSAIDs utilization in three hospitals in Guang'an from January 2005 to January 2008 [J]. Chinese Pharmacy. 2010; 21(10): 876-8.
2. Wu W F, Lv B. Non-steroidal anti-inflammatory drugs and related gastrointestinal diseases [J]. Gastroenterology. 2007; 10: 634-6.
3. Sun LB. Research progress on the mechanism of gastrointestinal diseases associated with NSAIDs [J]. Foreign Medicine (Internal Medicine). 1998; 5: 195-7, +200.
4. Li JT, Li ZS. Risk factors of non-steroidal anti-inflammatory drug-related gastrointestinal injury [J]. Foreign Medicine (Internal Medicine). 2001; 3: 123-126.
5. Wang YF, Ou Yang Q. Intestinal damage caused by NSAIDs [J]. Foreign Medicine (Internal Medicine). 2001; 5: 211-5.