

**Repair of a Perforated Duodenal Ulcer Using a Jejunal Serosal Patch: A Case Report**

Syed I, Tanveer S and Singh-Ranger D\*

The Royal Wolverhampton NHS Trust, UK

**\*Corresponding author:**

Mr Singh-Ranger,  
The Royal Wolverhampton NHS Trust, UK,  
E-mail: Deepak.singh-ranger@nhs.net

Received: 03 Nov 2022

Accepted: 21 Nov 2022

Published: 29 Nov 2022

J Short Name: AJSCCR

**Copyright:**

©2022 Singh-Ranger D, This is an open access article distributed under the terms of the Creative Commons Attribution License, which permits unrestricted use, distribution, and build upon your work non-commercially.

**Citation:**

Singh-Ranger D. Repair of a Perforated Duodenal Ulcer Using a Jejunal Serosal Patch: A Case Report. *Ame J Surg Clin Case Rep.* 2022; 6(2): 1-5

**Keywords:**

Peptic Ulcer; Duodenal Perforation; Jejunal Serosal Repair; Patch Procedure; Serosal

**Abbreviations:**

CT: Computed Tomography; SBP: Systolic Blood Pressure; ITU: Intensive Therapy Unit; CRP: C Reactive Protein; TPN: Total Parenteral Nutrition; AKI: Acute Kidney Injury; GCS: Glasgow Coma Scale; PPI: Proton Pump Inhibitor; DU: Duodenal Ulcer; RCT – Randomized Controlled Trial; ASA: American Society of Anaesthesiologists

**1. Abstract**

A 73-year-old gentleman was admitted to the hospital with ongoing abdominal pain, altered bowels habits, weight loss, and blood-stained vomitus. CT scan revealed evidence of duodenal perforation. The patient underwent laparotomy with repair of large duodenal ulcer perforation using a jejunal serosal patch. Post-operatively, the patient required ITU support, TPN, and an extended course of antibiotics. A water-soluble swallow done approximately 1 month post-operatively did not show any evidence of continued leak.

**2. Background**

Perforated duodenal ulcers are one of the commonest causes of peritonitis. Classically, a pediceled omental patch was used to “plug” defects in the duodenum [1]. This was later modified by the use of free omental grafts to patch over defects due to perforated duodenal ulcers [2]. However, in case of giant perforated duodenal ulcers, application of primary repair or omental patch repair is deemed inadequate, with imminent post-operative leaks [3,4]. In such cases, other surgical techniques may be deemed more appropriate. Perforated giant duodenal ulcers are associated with poor outcomes if inadequately repaired, as well as significant morbidity (20-70%) and mortality (15-40%) [5]. Patient dependent factors associated with high mortality rates include advanced age, comorbidities, poor haemodynamic status, larger size of perforation, delayed presentation to the hospital, and delayed surgical intervention [4]. In spite of the size of perforation being a vital factor in determining the outcome, the literature is deficient regarding the quantification of the size of perforated peptic ulcers. Gupta et al

has described giant perforated peptic ulcers as defects measuring more than 3 cm in size [6].

Early surgical intervention is indicated particularly in acutely ill patients with peritonism, and underlying giant perforated duodenal ulcers [4]. Among the surgical techniques used to repair perforated peptic ulcers are partial gastrectomy, jejunal serosal patch, jejunal pedicled graft, free omental plug, suturing of the omentum to the nasogastric tube, proximal gastrojejunostomy, and gastric disconnection [3, 7-11]. Literature reviews have demonstrated the reliability of jejunal serosal patch repair in cases of severely infected perforated peptic ulcers. The procedure was first described by Kobbold and Thal to outline its effectiveness in closing duodenal defects in canine models, followed by its clinical application in 1965 by James and Santa; they utilized a serosal patch to close a duodenal fistula in a 55-year-old male, with no post-operative continued leak [12]. Herein, we described a case of a 73-year-old male with a perforated duodenal ulcer that was repaired using a jejunal serosal patch.

**3. Case Report****3.1. Case History and Examination**

A 73-year-old male was admitted to the emergency department with abdominal pain, on and off for 2-3 months, along with post prandial blood-stained vomiting. He reported that for the last 2 days, the pain had become constant, localized to the epigastric region. On the day of admission, the patient had felt dizzy, and had had a fall – a source of concern for the patient and his family. However, the fall was not associated with any injury or loss of consciousness. The patient also stated alteration of bowel habits,

in addition to weight loss, which he had been referred to the fast-track colorectal clinic. The medical background was significant for hypertension, hypercholesterolemia, and basal cell carcinoma. There were no prior surgeries, or allergies. He did not take any NSAIDs, or blood thinners.

The medical examination revealed a frail, pale elderly gentleman, awake and alert with a GCS of 15/15, and some haemodynamic instability (SBP – 71 mmHg with normal pulse) on admission. His abdominal examination revealed a rigid abdomen with generalized tenderness, and involuntary guarding. Bowel sounds were audible.

### 3.2. Investigations, Treatment, and Outcome

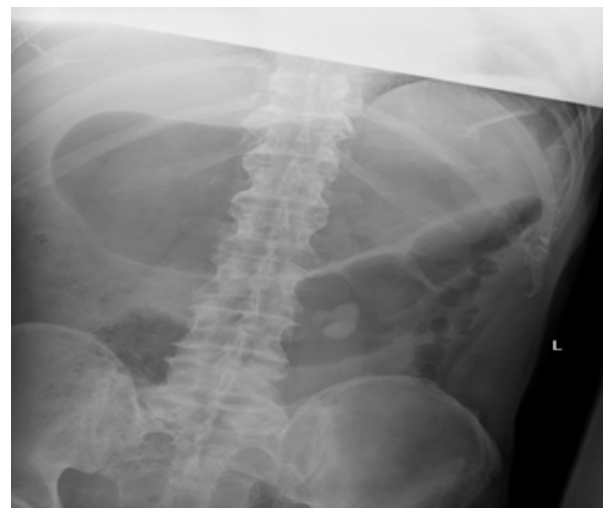
The routine blood samples taken on admission were significant for a raised white cell count of 17.5, with a CRP of 1.0 and a lactate of 7.09, whereas the rest of tests did not yield any pathological findings. A plain abdominal radiograph showed gas distended stomach but no pneumoperitoneum. (Figure 1). The patient was managed with intravenous fluids, antibiotics, analgaesics, and intravenous proton pump inhibitors while awaiting an urgent CT. During his admission, the patient's inflammatory markers worsened (CRP - 311 White cell count – 17.5), and his lactate rose to 8.39. The aforementioned blood results, coupled with the patient's compromised haemodynamic status, prompted urgent surgical intervention. The patient underwent laparotomy, with serosal patch repair of a perforated duodenal ulcer, and washout. Prior to the surgery, ITU team was taken on board for post-operative monitoring of the patient.

The operation was done under general anaesthesia. A midline laparotomy incision was made. The intra-operative findings were four quadrant biliary peritonitis, involving the entirety of bowel loops and the omentum. A perforated duodenal ulcer measuring 1.5 cm was seen at the junction of the first and second parts of the duodenum, with the ante-mesenteric border of the duodenum completely eroded by the ulcer.

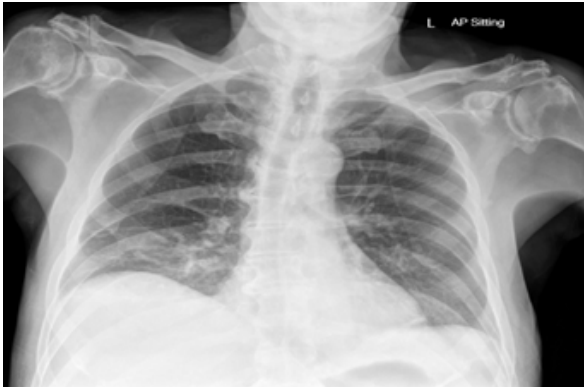
Four-quadrant washout was done using warm water, and the second part of the duodenum was kocherized. The lesser sac was entered to visualize the stomach and to determine the possibility of resection of the stomach. However, given the proximity of the ulcer to vital structures like the ampulla of vater, along with the perplexity involved with identifying the common bile duct, and the cystic duct due to severe chemical inflammation from the intraluminal contents, made it unsafe to proceed with resection. A decision was made to place a serosal patch over the perforated ulcer, using the proximal jejunum, which was held in place using 2/0 vicryl. Four Robinson's drains were placed, 1 in the area of the ulcer, 1 each in the right and left paracolic gutters, and 1 in the pelvis. The patient needed a post-operative admission to ITU for 6 days, owing

to his severely compromised haemodynamic status (Anuria and hypotension in spite of double nor-adrenaline support). He also developed new onset atrial fibrillation post operatively, which was managed with amiodarone. He was kept on ventilatory support for 3 days, following which he self-extubated and maintained saturation on room air. Vasopressor support was weaned off as well, as the patient was able to maintain a target mean arterial pressure of > 65mmHg.

The patient was stepped down to a surgical ward and was commenced on TPN. He was also managed with intravenous hydration to improve post operative AKI, as well as intravenous antibiotics, and intravenous PPI. A water-soluble swallow was done on the 9th post-operative day, which showed a contained focal leak in the 1st part of the duodenum (Figure 4) Hence, oral intake was not restarted, and TPN was continued. During his hospital course, the patient started spiking temperatures, and had a rise in inflammatory markers as there was suspicious of intraperitoneal collection as drain fell off. The patient received a course of Piperacillin/Tazobactam for 14 days, and fluconazole for 10 days. A repeat CT abdomen + pelvis was done, which showed a peri-splenic collection, (Figure 5) for which the patient underwent ultrasound guided aspiration. Following this, the patient clinically improved. A repeat water-soluble swallow done about 1 month post-operatively (Figure 6), showed no leak, following which oral intake was resumed, and the patient was weaned off TPN. The patient tolerated oral diet well and was soon back to his pre-operative baseline. After a hospital stay of 39 days, the patient was deemed medically fit for discharge to a rehabilitation centre on oral PPI for a total of 6 weeks with out-patient follow up.



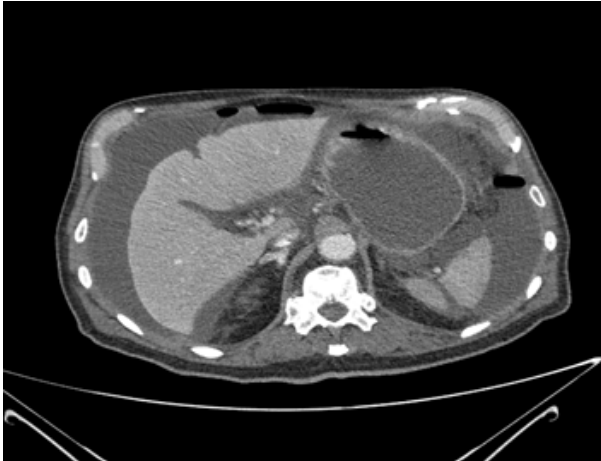**Figure 1:** Abdominal X-ray - Gas distended stomach. Few prominent large bowel loops.



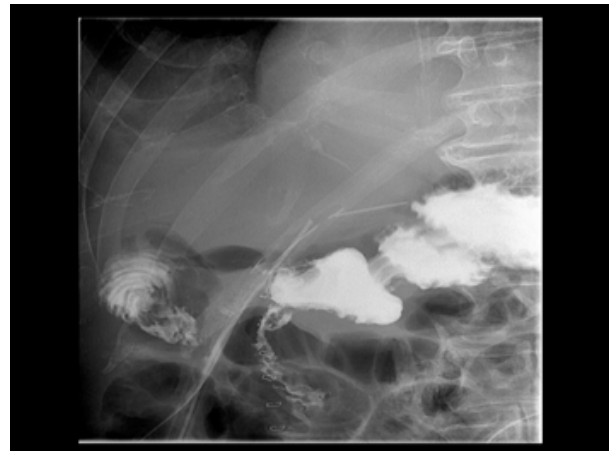
**Figure 2:** Erect Chest X-ray – No free air under diaphragm.



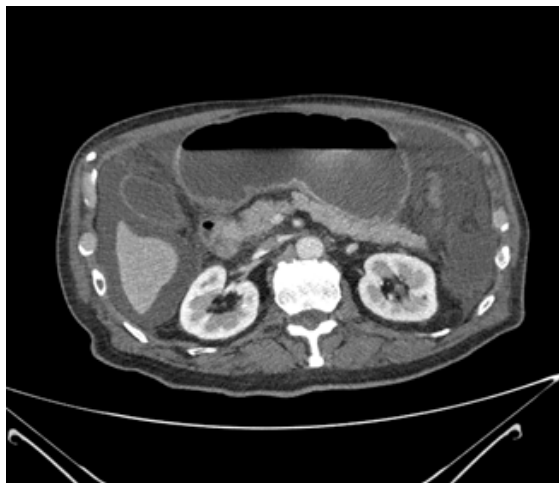
**Figure 4a:** Contained leak in first part of duodenum.



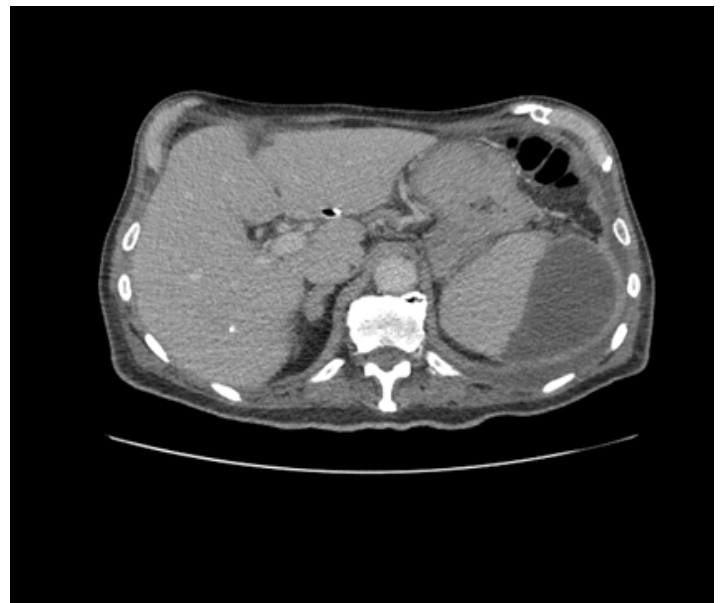**Figure 3a:** Distended stomach (Red arrow) Free air in peritoneal cavity (Blue arrow) Free fluid in peritoneal cavity (Green arrow).



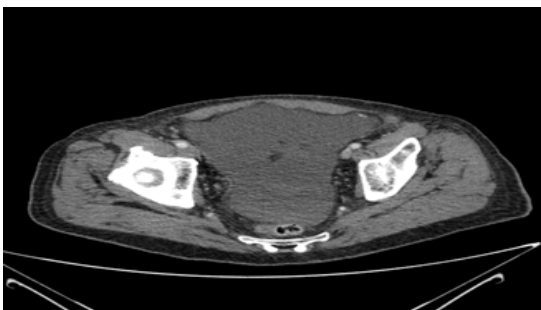
**Figure 4b:** Contained leak in first part of duodenum.



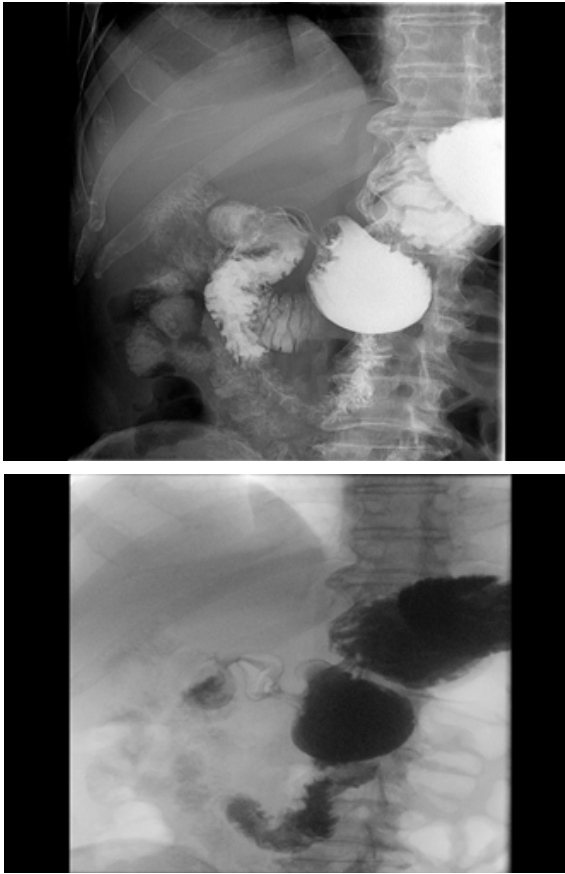
**Figure 3b:** Ill-defined pyloric opening (Red arrow) Small free air locules between the stomach and the gall bladder (Blue arrow).



**Figure 5:** Peri-splenic collection.



**Figure 3c:** Free fluid in pelvis (Red arrow).



Figures 6a and 6b: Duodenal leak resolved

#### 4. Discussion

Duodenal ulcer perforation is a frequently presenting surgical emergency, complicating 10-20% of all acid peptic diseases, of which approximately 1-2% are large/giant peptic ulcer perforations. These giant perforations carry a significant risk of morbidity (20-70%) and mortality (10-15%) [6,12,13].

The management of perforated peptic ulcers depends on multiple factors, chief among which is the size of the defect. According to Gupta et al, perforated peptic ulcers can be classified into the following categories:

Small perforations – Less than 1 cm

Large Perforations – 1 to 3 cm

Giant perforations - > 3 cm [6]

The surgical management of a perforated peptic ulcer entails an urgent surgical intervention, followed by a more definitive procedure done on an elective basis. The classic urgent surgical management of a perforated peptic ulcer is the plug the defect with a patch of omentum, either laparoscopically, or through an open approach [15]. In accordance with this definition, the perforated DU in our case fell in the category of a large perforation, since it measured 1-1.5 cm in size.

“Omental plugging” using a pediceled omental graft was the first surgical technique used for closure of duodenal ulcers in 1929 and was first described by Cellan Jones – a procedure that is now

deemed as the gold standard in managing perforated gastric ulcers. This involves placing a length of omentum over the deficiency in the duodenal wall and holding it in place using full thickness sutures on either side of the defect [1]. Later, in 1937, Graham used a free omental graft to repair duodenal defects from perforated peptic ulcers [2]. However, in case of large/giant perforations, the aforementioned techniques are considered inadequate and carry a high risk of post operative leak [3,4].

A thorough literature review did not yield any definitive guidelines regarding the management of large/giant duodenal ulcer perforations. Various authors have advocated for various techniques based on their experience and knowledge. These procedures include partial gastrectomy (Billroth I or II), Vagotomy and antrectomy, gastrotomy, lateral duodenostomy with feeding jejunostomy, plugging of defect using jejunal serosal patch or pediceled jejunal graft, or even suturing omentum to the NG tube [16,17]. Even though the main concern regarding the use of omental patch repair in large DU perforations is the risk of leak, it is important to note that none of the other surgical procedures mentioned are immune to post-operative leaks, rendering the original point moot [3,9]. Although literature fails to show any definitive difference in morbidity and mortality compared to primary repair, there are some case reports of a successful closure of giant perforated DU defects, a technique that was employed in the aforementioned case [18]. This involves mobilizing a jejunal loop (about 2 feet away from the Ligament of Treitz), approximating it to the duodenal defect, and holding it in place using sutures that pass through the duodenal wall and the seromuscular layers of the jejunum [19].

In addition to the surgical techniques used, the factors associated with an increased risk of post-operative leak are advanced age, co-existing medical conditions, poor haemodynamic status, late presentation to the hospital, and later surgical intervention. Additionally, the risk of post-operative leak is aggravated by tissue factors like severe defects, surrounding oedema, inflammation, as well as factors like high intra-luminal pressure, an everted duodenal mucosa, and pancreatic lytic reaction [11]. Since some of these risk factors were present in our case, a small focal leak in the first part of the duodenum was seen on the water-soluble swallow done on the 9th post-operative day. However, a repeat water-soluble swallow done approximately 1 month post-operatively showed that the leak had resolved. Post-operative care and rehabilitation in such cases are just as important as the surgical procedure itself. Small-scale RCTs in Turkey have inferred that in patients with a low ASA grade (I to II), early start of feeding reduced the length of the hospital stay by about 3 days [20]. In contrast, we did not restart feeding until all evidence of an on-going leak was resolved, approximately 1 month after the surgery. Furthermore, Wong et al concluded that the use of H. Pylori eradication therapy in patients with perforated DU reduces the recurrence of ulcers at 8 weeks and 1 year post-operatively [21]. The average hospital stay for pa-

tients with DU perforations is 25.4 days, approximately 15 days less than the hospital stay in our case, likely due to the post-operative complications [12].

## 5. Conclusion

Duodenal ulcer perforation is a common surgical emergency, associated with an exponential risk of morbidity and mortality if not managed appropriately. The classically employed technique of omental plugging might not be adequate for large or giant duodenal ulcer perforations, due to an imminent risk of post-operative leak. Consequently, over the years, multiple other surgical techniques have been used for the closure of such defects, although no consensus has been reached regarding the superiority of one technique over the other. The use of jejunal serosal patches for DU perforation defects has been described as having a favourable outcome, as is the case in our paper. Post-operative care and rehabilitation are imperative for reducing the length of hospital stay.

## 6. Conflict of Interest

The authors have no conflict of interest to declare.

## 7. Consent

Written informed consent was obtained from the patient for the purpose of publication of this case report and its accompanying images.

## References

1. Cellan-Jones CJ. A rapid method of treatment in perforated duodenal ulcer. *British medical journal*. 1929; 1(3571): 1076.
2. Graham RR. The treatment of perforated duodenal ulcers. *Surg Gynecol Obstet*. 1937; 64: 235-8.
3. Chaudhary A, Bose SM, Gupta NM, Wig JD, Khanna SK. Giant perforations of duodenal ulcer. *Indian Journal of Gastroenterology: Official Journal of the Indian Society of Gastroenterology*. 1991; 10(1): 14-5.
4. Jani K, Saxena AK, Vagharia R. Omental plugging for large-sized duodenal peptic perforations: a prospective randomized study of 100 patients. *Southern medical journal*. 2006; 99(5): 467-72.
5. Rajesh V, Chandra SS, Smile SR. Risk factors predicting operative mortality in perforated peptic ulcer disease. *Tropical Gastroenterology: Official Journal of the Digestive Diseases Foundation*. 2003; 24(3): 148-50.
6. Gupta S, Kaushik R, Sharma R, Attri A. The management of large perforations of duodenal ulcers. *BMC surgery*. 2005; 5(1): 1-5.
7. Karanjia ND, Shanahan DJ, Knight MJ. Omental patching of a large perforated duodenal ulcer: a new method. *Journal of British Surgery*. 1993; 80(1): 65.
8. McIlrath DC, Larson RH. Surgical management of large perforations of the duodenum. *Surgical Clinics of North America*. 1971; 51(4): 857-61.
9. Sharma D, Saxena A, Rahman H, Raina VK, Kapoor JP. Free omental plug: a nostalgic look at an old and dependable technique for giant peptic perforations. *Digestive Surgery*. 2000; 17(3): 216-8.
10. Jani K, Saxena AK. Management of large sized duodenal peptic perforations by omental plugging-a new technique: a prospective randomized study of 100 patients. *Indian J Surg*. 2000; 62: 134-8.
11. Cranford Jr CA, Olson R, Bradley III EL. Gastric disconnection in the management of perforated giant duodenal ulcer. *The American journal of surgery*. 1988; 155(3): 439-42.
12. Bekele A, Kassa S, Taye M. The jejunal serosal patch procedure: a successful technique for managing difficult peptic ulcer perforation. *East and Central African Journal of Surgery*. 2016; 21(3): 63-7.
13. Vashistha N, Singhal D, Makkar G, Chakravarty S, Raj V. Management of giant gastric ulcer perforation: report of a case and review of the literature. *Case Reports in Surgery*. 2016.
14. Asensio JA, Feliciano DV, Britt LD, Kerstein MD. Management of duodenal injuries. *Current problems in surgery*. 1993; 30(11): 1026-92.
15. Wendling MR, Linn JG, Keplinger KM, Mikami DJ, Perry KA, Melvin WS, et al. Omental patch repair effectively treats perforated marginal ulcer following Roux-en-Y gastric bypass. *Surgical endoscopy*. 2013; 27(2): 384-9.
16. Kutlu OC, Garcia S, Dissanaik S. The successful use of simple tube duodenostomy in large duodenal perforations from varied etiologies. *International journal of surgery case reports*. 2013; 4(3): 279-82.
17. Malangoni MA. Commentary: Perforated giant duodenal ulcers: what is the best treatment?. *The American journal of surgery*. 2009; 198(3): 324.
18. Sorour M, Ghazal AH, Kassem M, El-Khashab EA, Shehata G. Study of the role of jejunal serosal patch in the management of large gastroduodenal perforations. *Egypt J Surg*. 2012; 31: 3.
19. Saad AS, Fadl EM, El Sayed MA. Triple-tube drainage versus jejunal serosal patch for management of leaked perforated duodenal ulcer after initial omental patch repair. *The Egyptian Journal of Surgery*. 2021; 40(1): 224-30.
20. Gonenc M, Dural AC, Celik F, Akarsu C, Kocatas A, Kalayci MU, et al. Enhanced postoperative recovery pathways in emergency surgery: a randomised controlled clinical trial. *The American Journal of Surgery*. 2014; 207(6): 807-14.
21. Wong CS, Chia CF, Lee HC, Wei PL, Ma HP, Tsai SH, et al. Eradication of *Helicobacter pylori* for prevention of ulcer recurrence after simple closure of perforated peptic ulcer: a meta-analysis of randomized controlled trials. *Journal of surgical research*. 2013; 182(2): 219-26.