

Bilateral Patellar Tendon Rupture in a Patient with Uncontrolled Primary Hyperparathyroidism: A Case Report

Stokey PJ¹, SMitchell S¹, Cross JM¹ and Tank J²

¹Department of Orthopedics, University of Toledo Medical Center, Toledo, OH USA

²Department of Orthopedic Surgery, ProMedica Toledo Hospital, Toledo, OH USA

*Corresponding author:

Phillip J Stokey,
Department of Orthopedics, University of Toledo
Medical Center, Toledo, OH USA, 1125 Hospital
Drive, Toledo, OH 43614,
E-mail:Phillip.stokey@utoledo.edu

Received: 28 Mar 2022

Accepted: 12 Apr 2022

Published: 18 Apr 2022

J Short Name: AJSCCR

Copyright:

©2022 Stokey PJ. This is an open access article distributed under the terms of the Creative Commons Attribution License, which permits unrestricted use, distribution, and build upon your work non-commercially.

Citation:

Stokey PJ. Bilateral Patellar Tendon Rupture in a Patient with Uncontrolled Primary Hyperparathyroidism: A Case Report. *Ame J Surg Clin Case Rep.* 2022; 4(9): 1-4

1. Abstract

1.1. Case

A 32 year-old male presented to clinic with low-energy bilateral patellar tendon ruptures sustained 3 days apart. Further workup revealed significantly elevated parathyroid hormone (PTH) and calcium levels consistent with parathyroid adenoma. In conjunction with endocrine surgery, an en-bloc resection of his adenoma was performed followed by bilateral tendon repair. His postoperative course was complicated by rebound hypocalcemia, colloquially known as “hungry bone syndrome”.

1.2. Conclusion

This case demonstrates the importance of eliciting a comprehensive history in the setting of spontaneous tendon rupture. Furthermore, PTH homeostasis has a major association with tendon integrity that is important for surgeons to understand.

1.3. Introduction

Spontaneous tendon rupture in the setting of hyperparathyroidism has been a topic of interest since this phenomenon was first described in 1949 [1]. Patients presenting with patellar tendon rupture demonstrate an inability to actively extend the knee, and radiographs may be remarkable for patellar alta. However, hyperparathyroidism does not typically present with other overt symptoms, with over 80% of patients being completely asymptomatic. In the 20% that are symptomatic, these are typically nonspecific when viewed individually, including nephrolithiasis, polyuria, constipation, fatigue, and depression, often associated with the popular mnemonic “stones, groans, and moans” [2]. While the etiology tendon rupture has a wide differential, this case highlights the importance of considering an endocrine pathology.

2. Case Report

This is a 33-year-old male who initially came to the clinic with a one-day history of right knee pain and inability to ambulate after a ground-level fall. Past medical and surgical history were unremarkable aside from a recent history of nephrolithiasis, he took no medications, and social history was notable for smoking one pack per day. Upon evaluation, he was found to have no active knee extension and patella alta on radiographs (Figure 1) indicative of patellar tendon rupture. 3 days later he sustained another low energy fall and presented with similar findings on the left and was admitted for bilateral patellar tendon repair the following day due to his inability to ambulate. The following day, his labs were remarkable for a calcium of 14.8, which prompted an endocrine workup that revealed an elevated PTH (1,329) and a 2x3x3 cm thyroid mass consistent with parathyroid adenoma. After discussion with endocrine surgery and correction of his serum calcium, it was decided to proceed with joint en bloc parathyroidectomy followed by bilateral open patellar tendon repair. Intraoperatively, the ruptures were found near the inferior poles of either patella and repaired in the usual fashion using #5 nonabsorbable locking style stitches passed through three standard patellar tunnels (Figure 2). He was made weightbearing as tolerated in hinged knee braces locked in extension, but on postoperative day 1, he developed significant tetany and acute kidney injury and transferred to the ICU. This was caused by a refractory hypocalcemic state, a phenomenon known as “hungry bone syndrome”, and treated with 4 days of aggressive calcium / vitamin D supplementation and bisphosphonates. Active knee motion from 0-110 in the braces were initiated at 6 weeks, and at 1 year had range of motion from 0-120 and 5/5 extension strength bilaterally without pain, instability, or reinjury.

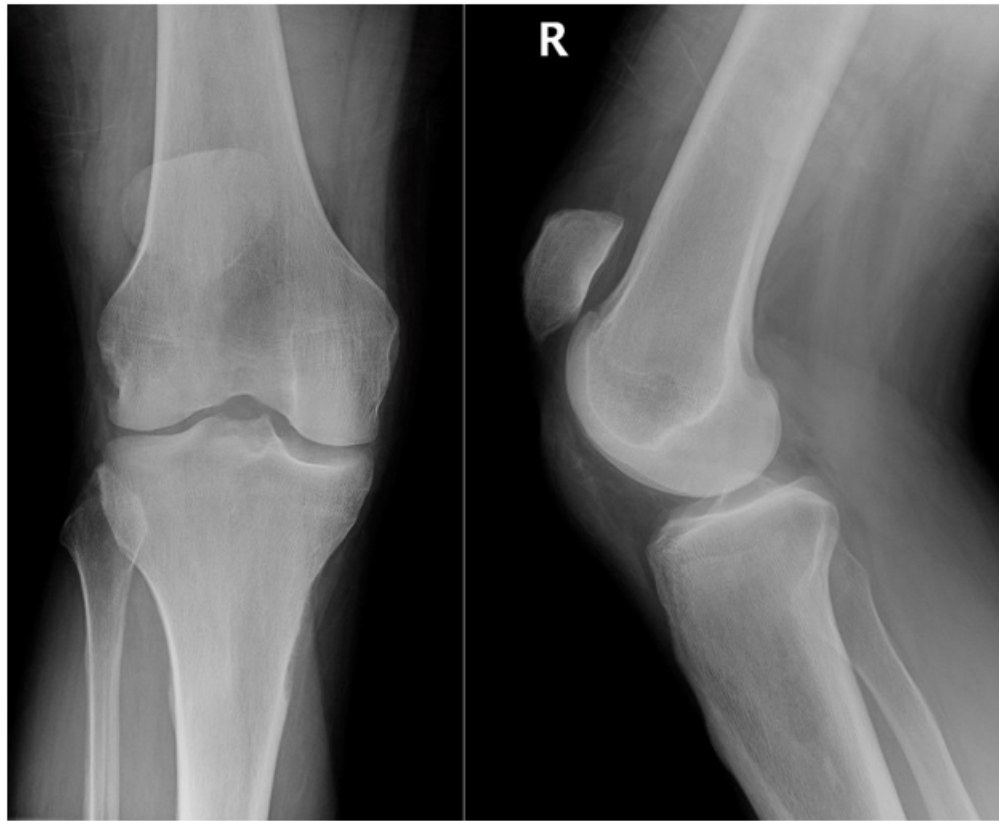


Figure 1: AP and lateral views of the right knee at the time of presentation, demonstrating patella alta.

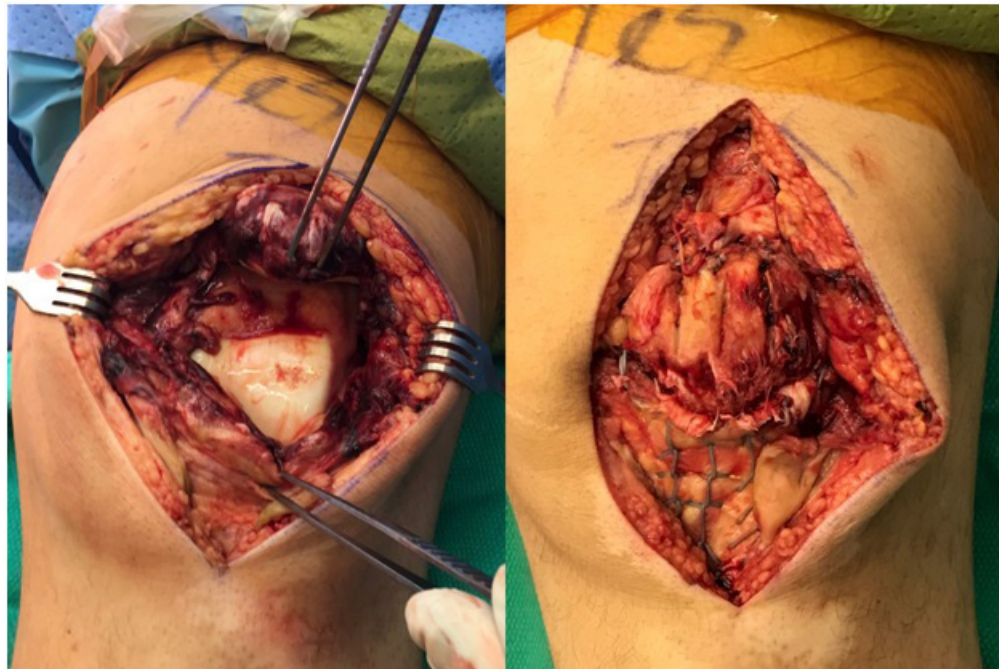


Figure 2: Intraoperative photos of the tendon rupture site (left) and subsequent repair (right).

3. Discussion

Literature has previously correlated spontaneous tendon rupture and complications of chronic renal dysfunction, including hyperparathyroidism, uremia, malnutrition, exposure to chronic acidosis, and amyloid deposition within soft tissue [3-6]. However, ascertaining a primary mechanism behind tendon weakening and subsequent rupture in the setting of renal failure has been confounded by the multitude of comorbidities that these patients often present with. Attempts to ascertain the precise etiology of spontaneous tendon rupture initially focused on patients with long-standing renal disease that had developed secondary hyperparathyroidism, as a notable contingent of patients presented with this complication following chronic hemodialysis [7]. In this scenario, renal disease results in insufficient renal synthesis of 1,25-hydroxy vitamin D, which ultimately leads to a reduction in serum calcium. Concurrently, a reduction in glomerular filtration rate (GFR) leads to an increased retention of serum phosphate, which sequesters free calcium within the blood and further reduces serum calcium levels. This inverse reduction in serum calcium and rise in serum phosphate levels results in abnormally high parathyroid hormone levels as the parathyroid glands attempt to compensate. With adequate monitoring and supplementation of patients' vitamin D and serum calcium levels, these consequences of renal failure can be avoided⁸. However, patients described in these various case reports were often found to be noncompliant with prophylactic therapies. Limited reports exist regarding hyperparathyroidism and spontaneous tendon rupture; the incidence of rupture varies among different tendons. Jones et al. conducted a meta-analysis examining reports of patients undergoing dialysis with tendon rupture between 1980 and 1995 and found the majority of patients suffered trauma to their quadriceps tendon(s) [6-8]. Other injuries found within the literature include achilles, triceps, patellar, and digital extensor tendon ruptures. Unique to this, patellar tendon rupture of individuals outside of athletics is exceedingly rare within the literature [9], and spontaneous bilateral patellar tendon rupture is even more unusual: Taylor et al. in 2009 reported approximately 50 reported cases of spontaneous bilateral patellar tendon rupture in the English and German literature [10]. Case reports have recently emerged regarding unusual tendon rupture patterns in patients with primary hyperparathyroidism due to the development of a parathyroid adenoma, as opposed to patients who have developed secondary hyperparathyroidism due to renal failure. The authors of this study found two reported cases of spontaneous bilateral patellar tendon rupture in relation to a patient who concurrently suffered from a parathyroid adenoma and excessively high PTH levels [11,12]. These reports suggest that high osteoclast activity and bone turnover due to excessive serum PTH levels may be a primary etiology leading to tendon failure. Supporting this idea, Rodeo et. al found that inhibiting osteoclastic activity resulted in significantly improved bone formation around grafted tendons in

rabbit models [13]. While the incidence is rare, our case highlights the importance of a thorough history and routine blood work for patients presenting with spontaneous low energy tendon rupture. We present this case to help inform other providers of the potential dangers of the "idiopathic" etiology, as well as guide workup and management of patients with tendon ruptures in the setting of pathologic primary or secondary hyperparathyroidism or unique clinical presentations like bilateral simultaneous ruptures. Additionally, we believe a single-stage adenoma resection and tendon repair is an appropriate treatment option that will not lead to adverse outcomes in a stable patient.

References

1. Steiner C A, Palmer L H. Simultaneous bilateral rupture of the quadriceps tendon. *The American Journal of Surgery*.1949; 78(5): 752-755.
2. Walker MD, Silverberg SJ. Primary hyperparathyroidism. *Nat Rev Endocrinol*. 2018; 14(2): 115-125.
3. Bhole R, Flynn JC, & Marbury TC. Quadriceps Tendon Ruptures in Uremia. *Clinical Orthopaedics and Related Research*. 1985; (195): 200-206.
4. Thauant M, Gaudin P, Naret C, Beaufils P, Thauant O. Role of secondary hyperparathyroidism in spontaneous rupture of the quadriceps tendon complicating chronic renal failure. *Rheumatology*. 2005; 45(2): 234-235.
5. Kurer M, Baillod R, Madgwick J. Musculoskeletal manifestations of amyloidosis: A review of 83 patients on haemodialysis for at least 10 years. *The Journal of Bone and Joint Surgery. British Volume*. 1991; 73(2): 271-276.
6. Jones N, Kjellstrand CM. Spontaneous tendon ruptures in patients on chronic dialysis. *American Journal of Kidney Diseases*. 1996; 28(6): 861-866.
7. Gao M, Yang H, Shi W. Simultaneous bilateral quadriceps tendon rupture in a patient with hyperparathyroidism undergoing long-term haemodialysis: A case report and literature review. *Journal of International Medical Research*. 2013; 41(4): 1378-1383.
8. Cunningham J, Locatelli F, Rodriguez M. Secondary Hyperparathyroidism: Pathogenesis, Disease Progression, and Therapeutic Options. *Clinical Journal of the American Society of Nephrology*. 2011; 6(4): 913-921.
9. Albayrak I, Kucuk A, Arslan S, Ozbek O. Spontaneous patellar tendon rupture in a case followed up for diagnosis of systemic lupus erythematosus. *European Journal of Rheumatology*. 2014; 1(4): 159-160.
10. Taylor BC, Tancev A, Fowler T. Bilateral patellar tendon rupture at different sites without predisposing systemic disease or steroid use. *Iowa Orthop J*. 2009; (29): 100-104.
11. Salah MM, Yong YR, Poh WT, Chong LR. Multiple spontaneous tendon ruptures from entheses failure in primary hyperparathyroidism: A case report and review of imaging findings. *Skeletal Radiology*. 2018; 48(8): 1279-1287.

12. Chen CM, Wang SJ, Wu SS, Chu P, Huang GS. Spontaneous Rupture of the Patellar and Contralateral Quadriceps Tendons Associated with Secondary Hyperparathyroidism in a Patient Receiving Long-term Dialysis. *Journal of the Formosan Medical Association*. 2006; 105(11): 941-945.
13. Rodeo SA, Kawamura S, Ma CB, Deng X, Sussman PS, Hays P, et al. The Effect of Osteoclastic Activity on Tendon-to-Bone Healing. *The Journal of Bone & Joint Surgery*. 2007; 89(10): 2250-2259.