

Pyopneumothorax Caused by Parvimonas Micra and Prevotella Oralis: A Case Report and Literature Review

Li Y, Yang J*, Wang J, Wei B and Hu L

Emergency Medicine Clinical Research Center, Beijing Chao-Yang Hospital, Capital Medical University, Beijing, China

*Corresponding author:

Jun Yang,
Emergency Medicine Clinical Research Center,
Beijing Chao-Yang Hospital, Capital Medical
University, Beijing, China,
E-mail: yangjun26@sina.com

Received: 16 Jan 2023

Accepted: 14 Mar 2023

Published: 23 Mar 2023

J Short Name: AJSCCR

Copyright:

©2023 Yang J, This is an open access article distributed under the terms of the Creative Commons Attribution License, which permits unrestricted use, distribution, and build upon your work non-commercially.

Citation:

Yang J. Pyopneumothorax Caused by Parvimonas Micra and Prevotella Oralis: A Case Report and Literature Review. *Ame J Surg Clin Case Rep.* 2023; 6(8): 1-5

Keywords:

Parvimonas micra; Prevotella oralis; pyopneumothorax

1. Abstract

Parvimonas micra and Prevotella oralis are both anaerobic pathogens that commonly cause periodontitis and are widely present in the oral cavity, gastrointestinal tract, and skin. These bacteria can cause infections in sites other than the oral cavity, but few cases causing severe pulmonary lesions have been reported thus far. Here, we report a case of pyopneumothorax caused by a co-infection of Parvimonas micra and Prevotella oralis.

2. Introduction

Parvimonas is a group of Gram-positive bacteria that are common anaerobic cocci in the oral cavity and the gastrointestinal tract and one of the pathogens of periodontitis [1], and Prevotella is a group of Gram-negative anaerobic bacteria that are found mainly in the oral cavity and intestinal tract and are mainly involved in periodontal infections [2]. In immunocompromised patients, the above-mentioned pathogens can cause infections in sites other than the oral cavity, such as bloodstream infections [3], infective endocarditis [4], liver abscesses [5], meningitis [6], and iliopsoas abscesses [7], but because of the atypical presentation and the difficulty of culture, it is often difficult to identify the pathogenic bacteria in a timely manner in clinical practice [8]. Here, we report a case of severe pneumothorax caused by a co-infection with Parvimonas micra and Prevotella oralis.

3. Case Presentation

On June 19, 2022, a 59-year-old male patient presented to the Emergency Center of Beijing Chaoyang Hospital, Capital Medical University, complaining of right chest pain and dyspnea. The patient was a long-term alcoholic but was not drunk when he had chest pain. Nine days before admission (June 10), he had intermittent right chest pain, which was knife-like pain, accompanied

by coughing and coughing yellow mucous sputum; four days ago (June 15), the right chest pain worsened, accompanied by dyspnea, and the volume of the coughing sputum increased significantly; and one day ago (June 18), the patient's chest pain symptoms continued to be unrelieved, and dyspnea progressively worsened, and he was referred to our emergency department. Chest computed tomography (CT) revealed right pleural enveloping effusion with infection and double lung inflammation (Figure 1A). The results of laboratory tests were as follows: white blood cell count (WBC) $11.8 \times 10^9/L$, C-reactive protein (CRP) 209.8mg/L, procalcitonin (PCT) 4.71ng/mL, and partial pressure of blood oxygen (PO₂) 71mmHg (oxygen concentration: 60%). Meropenem combined with vancomycin was given for anti-infection and closed drainage of the right side of the chest cavity; the drainage pus was yellow-green purulent pleural fluid with a foul odor (Figure 2). A repeat chest CT demonstrated that the right lung had reopened, and the left lung infection was more progressive than before (Figure 1B). The pus culture and the sputum culture were negative repeatedly. The results of next-generation sequencing (NGS) on the 5th day after admission (June 24) suggested Parvimonas micra (36.33%) and Prevotella oralis (17.23%), so metronidazole was added to fight the infection. The dentistry consultation confirmed the presence of chronic periodontitis, poor oral hygiene, tartar (++), and a large amount of plaque and soft tartar. On the 7th day after admission (June 26), fever started with a temperature of 37.8°C; the sputum culture suggested Candida albicans, and fluconazole antifungal treatment was added. On 8th day post admission (June 27), the body temperature returned to normal, and the sputum culture suggested pan-resistant Acinetobacter baumannii and Candida albicans, and tigecycline and sulfonamide anti-infection treatment was added. On the 11th day post admission (June 30), the sputum

culture suggested pan-resistant *Acinetobacter baumannii*, pan-resistant *Klebsiella pneumoniae*, and *Candida albicans*; the chest X-ray depicted that the left lung infection did not improve, and the WBC further increased to $29.1 \times 10^9/L$. Therefore, the anti-infective regimen was adjusted to cefoperazone sulbactam, linezolid,

amikacin, and fluconazole, after which the patient's infection index gradually decreased, and the review chest CT was better than before (Figure 1C). The patient was discharged after the improvement of his general condition. The microbiological culture results of the patient during hospitalization and the antimicrobial drug treatment are displayed in (Figure 3). We have obtained informed consent from the patient to publish the case details.

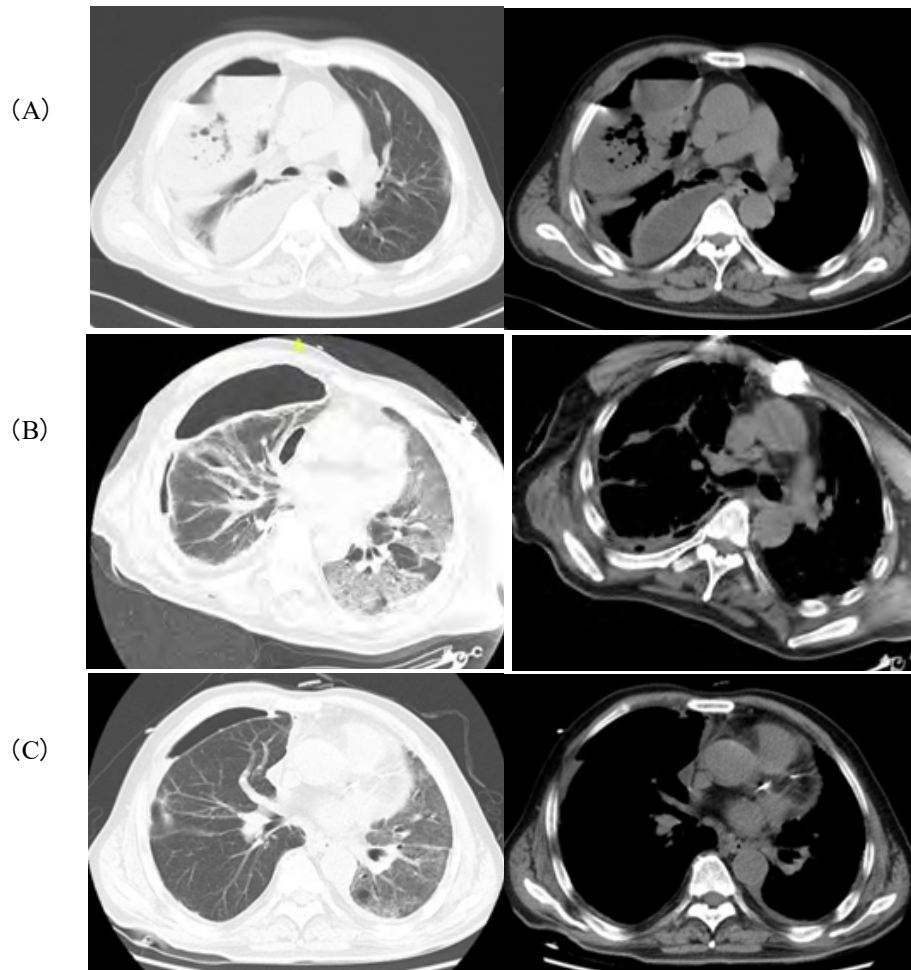


Figure 1: Comparison of chest CT before and after treatment: A: Before treatment (June 19): right pleural enveloping effusion with infection and double lungs inflammation; B: After chest drainage (June 21): right effusion decreased, right lung reopened, left lung progressed compared to before; C: Get better after treatment (August 5): right effusion and pneumonia improved significantly, left lung infection improved compared to before.



Figure 2: Closed drainage of yellow-green foul-smelling pus from the chest cavity.

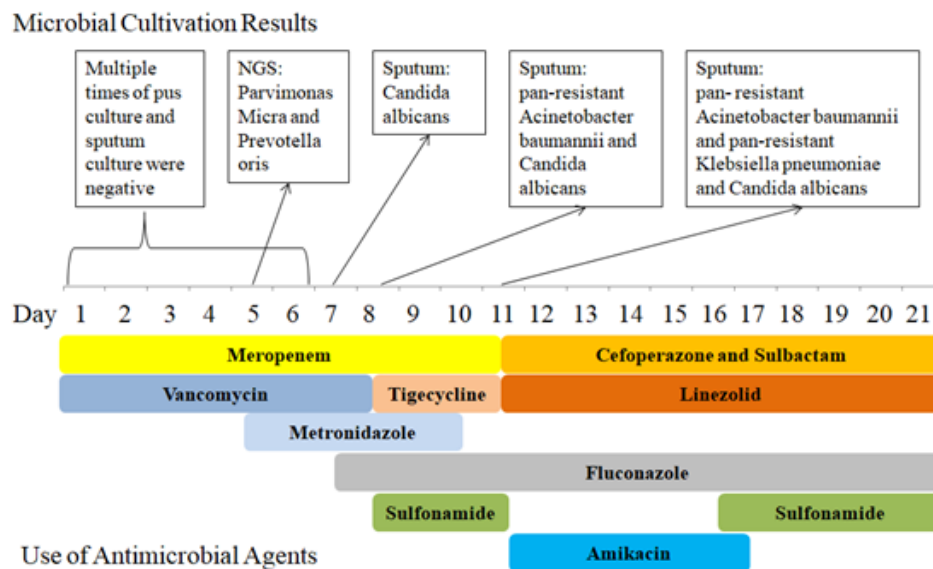


Figure 3: Microbiological culture results and antimicrobial drug treatment during the patient's hospitalization.

4. Discussion

Here, we report a case of pyopneumothorax caused by anaerobic bacteria associated with periodontitis. As the lung is an oxygen-rich organ, anaerobic bacteria-related infections rarely occur, and the pulmonary environment is unsuitable for the growth and reproduction of anaerobic bacteria such as *Parvimonas micra* and *Prevotella oralis*. Thus far, there have been very few reports of pneumonia caused by *Parvimonas micra* [9], and this patient had a co-infection of *Parvimonas micra* and *Prevotella oralis* causing pyopneumothorax combined with severe pneumonia, which is rare.

Parvimonas micra is a normal flora of the digestive system, genitourinary system, and skin, but not a dominant bacterium in an aerobic environment, and it is prone to causing periodontitis in poor oral conditions [1]. There have been several cases of abdominal infection [10], intervertebral discitis [11], lumbar muscle infection

[7] intracranial infection [10], and bloodstream infection [3] associated with *Parvimonas micra*, but there are few reported cases of severe pneumonia caused by it; there has been only one case of a 35-year-old female with cerebral hemorrhage, in which the sputum culture was negative several times, and an NGS examination of the bronchoalveolar lavage fluid revealed that the pathogen causing pneumonia was *Parvimonas micra* [9]. Because of the lack of specificity in the symptoms of infection of *Parvimonas micra* and the relative difficulty of the microbial culture, there is usually a lag in the clarification of the pathogenic bacteria and the adjustment of the anti-infective treatment; therefore, the application of the NGS technology can be used clinically as a supplementary means of pathogenic bacteria culture [12], particularly in the case of anaerobic bacterial infections with a low culture positivity rate. In addition, some of the lung abscesses formed by *Parvimonas micra* are difficult to distinguish from lung cancer in radiology, and the

use of NGS technology can clarify the disease diagnosis rapidly [13]. In the considered case, the microbiological culture of pus was negative, and the NGS examination results found *Parvimonas micra*. *Parvimonas micra* is sensitive to carbapenem, metronidazole, penicillin, vancomycin, and linezolid [14]. The abovementioned case reports are mostly of elderly patients or patients undergoing surgery and cancer treatment, suggesting that immune insufficiency and postoperative stress may be the risk factors for a *Parvimonas micra* infection, and our patient had no history of immune insufficiency or cancer, so we considered long-term alcohol abuse and poor oral hygiene in this patient as the main risk factors for this infection.

Prevotella oralis is mainly found in the oral cavity and the intestinal tract, particularly in the gingival crevices [14]. In addition to oral and periodontal infections, bloodstream infections [5, 15], neck abscesses [16], liver abscesses [5], meningitis [6], and breast abscesses [17] have been reported in patients with diabetes, post-surgical procedures, and immunosuppression. *Prevotella oralis* is an anaerobic bacterium with a low positive microbiological culture rate, and using NGS can significantly increase the positive rate of this bacterium [18]. The bacterium may be resistant to penicillin and clindamycin, with a documented resistance rate of 77% to penicillin and between 31% and 43.5% to clindamycin, and high sensitivity to carbapenem antibiotics [5].

Patients with anaerobic infections are highly susceptible to secondary infections with other bacteria, with most studies have reported that less than 50% of the anaerobic infections alone and more than half of the anaerobic infections are mixed [19] The British Pleural Society, in its 2010 Guidelines for the Management of Pleural Disease [20], stated that 65% of the community-acquired pleural infections had Gram-positive aerobic microorganisms as the causative agent, and 12%–34% of the patients had anaerobic infections. However, with the development of anaerobic detection methods and isolation techniques, researchers found that anaerobes are present in up to 76% of the cases, and in approximately 14% of the patients, anaerobes may be the only pathogen found.

In our case, the NGS was positive for anaerobic bacteria upon admission, and the symptoms did not show remission significantly after the administration of the anti-anaerobic treatment; instead, fever developed, which, combined with the patient's long-term alcohol abuse, immunosuppressed population, and treatment with carbapenems advanced antibiotics in the pre-course of the disease, suggested the occurrence of nosocomial infection, and the pathogen, in this case, was *Acinetobacter*. *Acinetobacter* is capable of accumulating multiple antibiotic resistance genes, resulting in multi-drug resistant or pan-drug resistance strains [21], and the mechanisms of resistance often expressed by hospital-based strains of *Acinetobacter* include the acquisition of β -lactamases [22], altered cell wall channels, and efflux pumps [23], which may be the mechanism for the development of *Acinetobacter* infections

in such patients.

There are some limitations of our case report. First, we did not find *Parvimonas micra* and *Prevotella oralis* in the blood, sputum, or pus cultures. Second, because of the high cost, we did not perform NGS testing on the oral cavity to further clarify the homology of the pyopneumothorax pathogens, nor did we send the sputum or the bronchoalveolar lavage fluid for NGS after treatment to clarify whether *Parvimonas micra* and *Prevotella oralis* were eradicated after treatment.

In conclusion, identifying the pathogenic organism is the key to treating infections such as pneumonia, and NGS allows for a rapid and accurate diagnosis when the bacterial culture results do not match the clinical presentation.

References

1. Kumar PS. Smoking and the subgingival ecosystem: a pathogen-enriched community. *Future Microbiol.* 2012; 7(8): 917-919.
2. Sampaio-Maia B, Caldas I M, Pereira ML. The Oral Microbiome in Health and Its Implication in Oral and Systemic Diseases. *Adv Appl Microbiol.* 2016; 97: 171-210.
3. Watanabe T, Hara Y, Yoshimi Y. Clinical characteristics of bloodstream infection by *Parvimonas micra*: retrospective case series and literature review. *BMC Infect Dis.* 2020; 20(1): 578.
4. Morinaga H, Kato K, Hisagi M. Purulent pericarditis-induced intracardiac perforation and infective endocarditis due to *Parvimonas micra*: a case report. *Eur Heart J Case Rep.* 2021; 5(2): a528.
5. Cobo F, Pérez-Carrasco V, Pérez-Rosillo MÁ. Bacteremia due to *Prevotella oris* of probable hepatic origin. *Anaerobe.* 2022; 76: 102586.
6. Frat J P, Godet C, Grollier G. Cervical spinal epidural abscess and meningitis due to *Prevotella oris* and *Peptostreptococcus micros* after retropharyngeal surgery. *Intensive Care Med.* 2004; 30(8): 1695.
7. Sawai T, Koga S, Ide S, et al. An iliopsoas abscess caused by *Parvimonas micra*: a case report. *J Med Case Rep.* 2019; 13(1): 47.
8. Dietvorst M, Roerdink R, Leenders A. Acute Mono-Arthritis of the Knee: A Case Report of Infection with *Parvimonas Micra* and Concomitant Pseudogout. *J Bone Jt Infect.* 2016; 1: 65-67.
9. Yu Q, Sun L, Xu Z. Severe pneumonia caused by *Parvimonas micra*: a case report. *BMC Infect Dis.* 2021; 21(1): 364.
10. Cesta N, Foroghi B L, Neri B. Multiple hepatic and brain abscesses caused by *Parvimonas micra*: A case report and literature review. *Anaerobe.* 2021; 69: 102366.
11. Durovic A, Eberhard N, Schären S. *Parvimonas micra* as a rare cause of spondylodiscitis - case series from a single centre. *Swiss Med Wkly.* 2020; 150: w20272.
12. Zhao Y, Chen J, Bai B. Pathogen determination from clinical abscess fluids using metagenomic next-generation sequencing. *Folia Microbiol (Praha).* 2021; 66(2): 197-202.
13. Zhang Y, Song P, Zhang R. Clinical Characteristics of Chronic Lung Abscess Associated with *Parvimonas micra* Diagnosed Us-

- ing Metagenomic Next-Generation Sequencing. *Infect Drug Resist.* 2021; 14: 1191-1198.
14. Brazier J, Chmelar D, Dubreuil L. European surveillance study on antimicrobial susceptibility of Gram-positive anaerobic cocci. *Int J Antimicrob Agents.* 2008; 31(4): 316-320.
 15. Bein T, Brem J, Schüsselbauer T. Bacteremia and sepsis due to *Prevotella oris* from dentoalveolar abscesses. *Intensive Care Med.* 2003; 29(5): 856.
 16. Shi H, Yang Z, Li H. Efficacy of needle aspiration in patients with oral-maxillofacial abscesses: A retrospective study of 15 consecutive patients[J]. *Am J Otolaryngol.* 2022; 43(1): 103216.
 17. Glazunova O O, Launay T, Raoult D. *Prevotella timonensis* sp. nov., isolated from a human breast abscess[J]. *Int J Syst Evol Microbiol.* 2007; 57(Pt 4): 883-886.
 18. Riggio M P, Lennon A. Development of a novel PCR assay for detection of *Prevotella oris* in clinical specimens. *FEMS Microbiol Lett.* 2007; 276(1): 123-128.
 19. Maskell NA, Batt S, Hedley EL. The bacteriology of pleural infection by genetic and standard methods and its mortality significance. *Am J Respir Crit Care Med.* 2006; 174(7): 817-823.
 20. Davies HE, Davies RJ, Davies CW. Management of pleural infection in adults: British Thoracic Society Pleural Disease Guideline 2010. *Thorax.* 2010; 65(2): i41-i53.
 21. Hsueh PR, Teng LJ, Chen CY. Pandrug-resistant *Acinetobacter baumannii* causing nosocomial infections in a university hospital, Taiwan. *Emerg Infect Dis.* 2002; 8(8): 827-832.
 22. Bonomo R A, Szabo D. Mechanisms of multidrug resistance in *Acinetobacter* species and *Pseudomonas aeruginosa*. *Clin Infect Dis.* 2006; 43(2): S49-S56.
 23. Peleg AY, Adams J, Paterson DL. Tigecycline Efflux as a Mechanism for Nonsusceptibility in *Acinetobacter baumannii*. *Antimicrob Agents Chemother.* 2007; 51(6): 2065-2069.