

Pseudomyxoma Peritonei: A Case Report and Review of the Literature

El Hachami FZ^{1*}, Imami Y¹, Berrehili H¹, Guezri A¹, Benchrifi Y², Benhessou M³, Ennachit M³, Elkerroumi M³

¹Gynecology obstetrics residents at CHU IBN ROCHD Casablanca, morocco

²Assistant professor of Gynecology obstetrics at Gynecology Department of the Center, Mohamed IV CHU IBN ROCHD Casablanca, morocco

³Professors of Gynecology obstetrics at: Gynecology Department of the Center, Mohamed IV, CHU Ibn Rochd Casablanca, Morocco

*Corresponding author:

Fatim Zohra El hachami
Onco- Gynecology Department of the Center,
Mohamed IV- Gynecology Department B, CHU Ibn
Rochd Casablanca, Morocco

Received: 02 Jan 2024

Accepted: 27 Jan 2024

Published: 02 Feb 2024

J Short Name: AJSCCR

Copyright:

©2024 El Hachami FZ, This is an open access article distributed under the terms of the Creative Commons Attribution License, which permits unrestricted use, distribution, and build upon your work non-commercially.

Citation:

El Hachami FZ. Pseudomyxoma Peritonei: A Case Report and Review of the Literature. Ame J Surg Clin Case Rep. 2024; 7(9): 1-4

Keywords:

Pseudomyxoma Peritonei; Appendix; Ovary;
Intraperitoneal Chemotherapy

1. Abstract

Pseudomyxoma peritonei is a clinical entity characterized by gelatinous ascites associated with mucinous deposits disseminated over the peritoneum and potentially invading abdominal organs. It is considered a tumoral process linked in the vast majority of cases to a mucinous appendicular tumor or one of ovarian origin. Pseudomyxomas can benefit from a therapeutic approach combining complete cytoreduction surgery and chemotherapy. The aim of this work is to analyze the epidemiological characteristics, clinical, evolutionary and therapeutic outcomes, through a case study of histologically confirmed peritoneal pseudomyxoma managed at the Mohammed VI center service of the University Hospital of Casablanca.

2. Identity

The patient was 54 years old, postmenopausal for 3 years, with

a history of a left cystectomy performed in 2019 in a peripheral hospital for a calcified cyst with no sign of malignancy on the pathological result. Two years after this operation, she consulted for abdominal distention associated with chronic pelvic pain in a state of conservation of general condition. Abdomino-pelvic MRI revealed abundant ascites, more marked in the pelvis, with several peritoneal nodules, creating a mass measuring 52x45mm, which was responsible for scaloppings on the lower border of the right liver and on the body of the uterus. The rest of the organs were without abnormalities, notably the appendix. Tumor markers were positive, notably CA 125 at 90.42U/ml. A diagnostic laparoscopy was performed, revealing a gelatinous ascites of moderate abundance covering the peritoneum, stomach and omentum, which was aspirated, and the presence of a mass adherent to the uterus and right adnexa, which was biopsied. The pathological result showed a grade 3 pseudomyxoma peritonei. Patient was referred to the oncology department for additional adjuvant treatment (Figure 1-3).

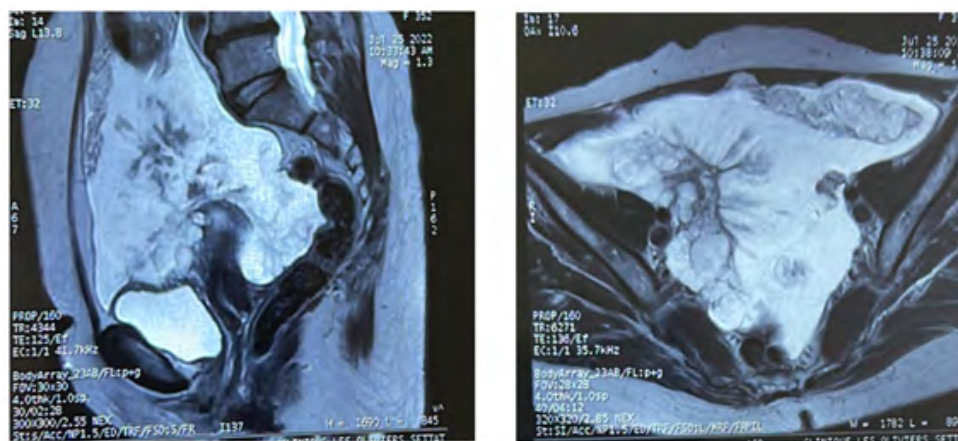


Figure 1: Right latero-uterine mass with abundant ascites and diffuse peritoneal carcinosis [(A) - sagittal section; (B) - axial section].

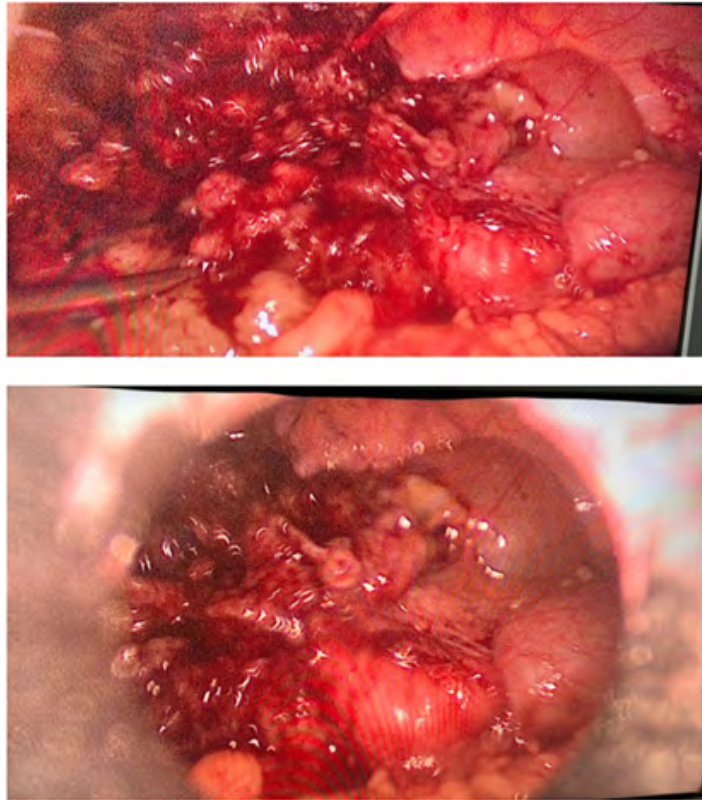


Figure 2: Adherent mass in uterus and right adnexa. [(A), (B)].

- Grade 1 : dépôts mucineux peu cellulaires, atypies de bas grade, absence d'invasion de type infiltratif (destructrice) ;
- Grade 2 : dépôts mucineux hypercellulaires, atypies de haut grade, invasion de type infiltratif (destructrice), se caractérisant par des glandes anguleuses, dans un stroma desmoplasique ou des amas tumoraux au sein de flaques de mucine de petite taille ;
- Grade 3 : dépôts mucineux avec présence de cellules en bague à chaton (*Digestive System Tumours WHO Classification of Tumours 2019*).

Figure 3: Classification histologique de l'OMS 2019 (5ème édition)

3. Discussion

Pseudomyxoma peritonei is a pathology first described by Karl F. Rokitansky in 1842, then reported in 1884 by Werth. [5]. It is a clinico-radiological condition defined by localized or diffuse accumulation of mucin in the abdominal and/or pelvic cavity. It belongs to the group of rare diseases of the peritoneum, with an estimated incidence of 1 to 2 cases per million inhabitants per year [1]. Its development is generally associated with the rupture of appendicular mucinous tumors and other mucinous tumors of the gastrointestinal tract or ovaries. Pseudomyxoma peritonei is generally divided into three types: low-grade, high-grade and high-grade with ring cells. The stage of the disease is determined by the peritoneal cancer index [13]. Thanks to immunohistochemistry and molecular engineering, it is now accepted that peritoneal pseudomyxoma is mainly of appendicular origin, more rarely the ovary, notably the

teratomatous lesion [1].

There is much debate as to whether ovarian tumours are secondary to appendicular tumours or independent primary ovarian tumours [3]. Immunohistochemical studies of the CK7, CK20 and HAM-56 antigens have shown that the origin of pseudomyxoma is most often appendicular [2]. In addition, several studies of K-ras gene mutations and loss of alleles on chromosomes 18q, 17p, 5q and 6q have demonstrated the presence of these abnormalities in peritoneal pseudomyxoma, which are absent in ovarian tumour pathology [4]. The only primary ovarian tumours capable of genuine pseudomyxomatous dissemination are mature cystic teratomas, probably due to the existence of a gastrointestinal contingent in these embryonic tumours [5]. 3 to 8% of cases are associated with peritoneal pseudomyxoma and mature ovarian cystic teratomas [1;6].

The clinical course is variable, non-specific and may be asymptomatic or with digestive symptoms, notably the presence of chronic pelvic pain, progressive abdominal distension or obstructive symptoms [9]. Radiologically, ultrasonography may reveal intra-peritoneal effusion, small cystic lesions, mucinous implants, or a hepatic and splenic imprint forming a scalloping pattern. CT is the examination of choice, revealing abundant hypodense peritoneal effusion, often compartmentalized and dense due to mucin deposition. Pathognomonic of pseudomyxoma is the “scalloping” or indentation of these viscera due to mucinous compression and fibrosis of the organs [9]. CT scans can also be used to search for primary tumors: appendicular, ovarian, colonic mucocele, pancreatic cystadenocarcinoma or urachal cystadenocarcinoma. Serum levels of the markers ACE, CA19-9 and CA125 can therefore be used to assess the biological aggressiveness of PMP. Their increase correlates with the extent of carcinosis and is a prognostic factor. Diagnosis is based on the presence of mucin in the peritoneal cavity, accompanied by cystic epithelial implants on the peritoneal surfaces. These lesions vary in size from a few mm to several centimetres. Confirmation is provided by histological analysis of peritoneal samples [14]. The morphological appearance (grade) and extent (stage) of the disease are prognostic factors.

The basic histological criteria for grading PMP are as follows:

Cellularity of Mucinous Deposits: hypo- or hypercellularity

Architectural Abnormalities: low or high grade

Cytological Abnormalities: low or high grade,

Kitten-Ring Cells: presence or absence,

Organ Invasion: presence or absence.

If present, type of invasion: expansive (so-called “pushing”) or infiltrative.

Various histological classifications have been proposed, the latest of which is WHO 2019 (5th edition). The treatment of pseudomyxoma peritonei is not yet standardized. The gold standard remains cytoreduction surgery followed by hyperthermic intraperitoneal chemotherapy [7]. This therapeutic approach results in 5- and 10-year overall survival rates of 90% and 85% respectively [10]. Resection is considered complete if no mass greater than 2.5 mm remains [15]. When complete cytoreduction surgery is not feasible, due to extensive involvement, palliative debulking surgery is performed, the aim of which is to remove as much gelatin and tumour formations as possible. Intraperitoneal chemotherapy (CHIP) or Hyperthermia Intraperitoneal Chemotherapy (HIPEC) aims to eradicate residual microscopic disease [11]. Adjuvant chemotherapy with 6 cycles of paclitaxel and carboplatin has been described in some cases, but no study has demonstrated the benefit of this chemotherapy [5,6]. As for recurrence, no intraperitoneal recurrence has been reported for pseudomyxoma peritonei of ovarian

origin [7]. Symptomatic recurrences may present as intestinal obstruction, abdominal pain or abdominal distension, which are treated again with debulking surgery [12]. The prognosis of peritoneal pseudomyxoma depends on complete cytoreduction surgery and the degree of malignancy of the tumour cells. Follow-up should take place 3 months after surgery and every 6 months, using CT scans and tumour marker assays to monitor recurrence [1].

4. Conclusion

Pseudomyxoma peritonei is a rare entity, most often of appendicular origin but which may also be of ovarian origin, with vague and non-specific symptoms. Diagnosis is usually made by imaging and confirmed by histology. Treatment is based on complete cytoreduction surgery combined with hyperthermic chemotherapy. Prognosis depends on histological grade, as well as rapid diagnosis and management.

References

1. Mohtaram A, Boutayeb S, El Youbi MBA, Sghiri T, Aaribi I, Kettani F, et al. Joint recommendations with RENAPE (National Network for the Management of Rare Peritoneal Tumors). TNCD - Chapter 16: Pseudomyxoma peritonei.
2. Peritoneal pseudomyxoma resulting from an ovarian teratoma associated with a borderline mucinous tumor: report of a case and review of the literature. 2013.
3. Ronnett BM, Shmooker BPM, Dienerwest M et al. Immunohistochemical evidence supporting the appendiceal origin of pseudomyxoma in women. *Int J Gynecol Pathol.* 1997; 16(1): 1-9.
4. O’Connell JT, Tomlinson JS, Roberts AA. Pseudomyxoma peritonei is a disease of MUC2-expressing goblet cells. *Am J Pathol.* 2002; 161(2): 551-64.
5. Szych C, Staebler A, Connolly DC. Molecular genetic evidence supporting the clonality and appendix origin of pseudomyxoma peritonei in women. *Am J Pathol.* 1999; 154(6): 1849-55.
6. Saluja M, Diane N, Kenwright, John P Keating. Pseudomyxoma Peritonei arising from a mucinous borderline ovarian tumor: Case report and literature review. *Aust N Z J Obstet Gynaecol.* 2010; 50(4): 399-403.
7. Hwang JH, So KA, Modi G, Lee JK, Lee NW, Lee KW, Kim I. Borderline-like mucinous tumor arising in mature cystic teratoma of the ovary associated with pseudomyxoma peritonei. *Int J Gynecol Pathol.* 2009; 28(4): 376-80.
8. Lee KR, Scully RE. Mucinous tumors of the ovary: a clinicopathologic study of 196 borderline tumors (of intestinal type) and carcinomas, including an evaluation of 11 cases with ‘pseudomyxoma peritonei’. *Am J Surg Pathol.* 2000; 24(11): 1447-64.
9. Bouia M, Hammoune N, Sliouia B, Bellasria S, Haouaneb MA, Azamib MA, et al. Peritoneal pseudomyxoma: imaging of a rare cause of gelatinous ascites through two cases. Radiology Department, Avicenne Military Hospital Marrakech, Morocco. b. Anatomical pathology department, Avicenne Military Hospital Marrakech, Morocco.

10. Dartigues P, Isaac S, Villeneuve L, Glehend O, Capovilla M, Chevalier A, et al. Update on pseudomyxoma peritonei: Anatomy-pathological aspects, and therapeutic implications.
11. Hettinga JV, Konings AW, Kampinga HH. Reduction of cellular cisplatin resistance by hyperthermia — a review. *Int J Hyperthermia* 1997; 13: 439—57.
12. Eveno C, Dagois S, Guillot E, Gornet JM, Pocard M. Treatment of peritoneal carcinomatosis by surgery and intraoperative intraperitoneal chemotherapy (HIPEC): new developments but also validated indications. *Taurus cancer*. 2008; 95 (1): 141-5.
13. Bartoška P, Vitek P, Marx J, Kopic J, Holečková P, et al. Peritoneal pseudomyxoma PMID: 31610663.
14. Sugarbaker PH, Ronnett BM, Archer A, Averbach AM, Bland R, Chang D, et al. Pseudomyxoma peritonei syndrome. *Advanced surgeon*. 1996; 30: 233-80.
15. Chua TC, Moran BJ, Sugarbaker PH, Levine EA, Glehen O, Gilly FN, et al. Data on early and long-term outcomes of patients with pseudomyxoma peritonei of appendiceal origin treated with a strategy of cytoreductive surgery and hyperthermic intraperitoneal chemotherapy. *J Clin Oncol*. July 10, 2012; 30(20): 2449-56.
16. Bo Yu, Moses S. Raj. Peritoneal pseudomyxoma.