

A Case Report of Kearns-Sayre Syndrome With Thyroid-Associated Ophthalmopathy

Li J^{1*}, Zhang W², Huang Q³ and Chen Y⁴¹Department of Ophthalmology, Peking University Shenzhen Hospital, Shenzhen, China²Department of Ophthalmology, Peking University Shenzhen Hospital, Shenzhen, China³Department of Ophthalmology, Peking University Shenzhen Hospital, Shenzhen, China⁴Department of Ophthalmology, Peking University Shenzhen Hospital, Shenzhen, China***Corresponding author:**

Jinying Li,
 Department of Ophthalmology, Peking
 University Shenzhen Hospital,
 Shenzhen, Guangdong 518036, China,
 Tel: 86-0755-83923333.
 Fax: 86-0755-83923333.
 E-mail: ljy951019@163.com

Received: 08 Apr 2021

Accepted: 27 Apr 2021

Published: 03 May 2021

Copyright:

©2021 Li J. This is an open access article distributed under the terms of the Creative Commons Attribution License, which permits unrestricted use, distribution, and build upon your work non-commercially.

Citation:

Li J, A Case Report of Kearns-Sayre Syndrome With Thyroid-Associated Ophthalmopathy. *Ame J Surg Clin Case Rep.* 2021; 3(1): 1-3.

Keywords:

Case Report; Kearns-Sayre Syndrome; Thyroid-Associated Ophthalmopathy

&Authors' contributed:

Li J, Zhang W, Huang Q, Chen Y are contributed equally to this work.

1. Abstract: A 27-year-old female complained about ptosis and proptosis who was ever diagnosed with myasthenia gravis, thymoma and hyperthyroidism. After treatment of thymectomy and other related treatment, her condition was not improved. And she suffered from eyeball movement disorder and low visual ability later. The proptosis measured by computed tomography was confirmed. Both eyeballs were in a fixed position and the examination of visual field revealed that both eyes were in tubular visual field. Electrocardiograms and the level of TSH was also abnormal. The patient was mainly diagnosed with Kearns-Sayre syndrome and thyroid-associated ophthalmopathy. The differential diagnosis is puzzling sometimes because the clinical symptoms and signs of TAO and KSS are similar. Clinicians should pay more attention to recognize them so as to take intervention early and improve their quality of life and prognosis.

Chronic Progressive External Ophthalmoplegia (CPEO) is a common subtype of mitochondrial encephalomyopathies. It presents with progressive ptosis and ocular dyskinesia, some of which may be accompanied with limb myasthenia, pigmentary retinopathy, deafness, diabetes, heart block and endocrine abnormalities. When the patients with CPEO are diagnosed with pigmentary retinopathy before 20 years old, they are considered as Kearns-Sayre Syndrome (KSS) [1]. KSS has been reported and discussed in many researches, but KSS with Thyroid-Associated Ophthalmopathy

(TAO) has not been reported yet. The incidence of KSS with TAO is rare and it is easy to be misdiagnosed and mistreated in clinical work accidentally. Currently, we report a case of KSS with TAO and make a further discussion in our paper. We have obtained the written informed consent from patient for publication. All procedures performed in studies involving human participant were in accordance with the Helsinki declaration.

2. Case presentation

A 27-year-old female came to our hospital, complaining about ptosis with 24 years and proptosis with 16 years. She said that she developed blepharoptosis at the beginning and then came to see the doctor with her family. She was diagnosed with Myasthenia Gravis (MG), thymoma and hyperthyroidism. After treatment of thymectomy, the degree of blepharoptosis had not been improved. The effect of oral pyridostigmine was not good, either. Later, she took thiamazole tablets continuously to keep herself in a stable condition. Unfortunately, she suffered from progressive bilateral proptosis, ocular dyskinesia and decreased dark vision 16 years ago, without diplopia. However, she did not go to hospital to get the special assessment. After accepting the treatment of hyperthyroidism with iodine-131 6 years ago, she got hypothyroidism and was treated with levothyroxine sodium tablets. She was not referred to ophthalmologist ever before. Now she came to our ophthalmology department so as to solve the problem of proptosis,

eyeball movement disorder and low visual ability. Family genetic history was denied and family members had no similar history.

The best corrected visual acuity was 16/40 and 4/40 respectively and the intraocular pressure was normal. The proptosis of both eyes measured by Computed Tomography (CT) was 20mm. Besides, the upper eyelid of both eyes covered about 4mm below the upper corneal margin when she saw forward (Figure 1). The muscle strength of the elevator palpebral was 1mm and eyelid could be closed completely. Anterior segment examination was normal. We found that the edge of the optic disc was clear but the retinal arteries were small and a massive of pigmentation could be seen in the posterior pole and surrounding of retina (Figure 2). The left eye was in an external oblique position which caused the optic disc could not have been photographed. The corneal reflection test of right eye was normal but the left eye was about -15Δ . Both eyeballs were in a fixed position and the movement of them in all directions was limited.

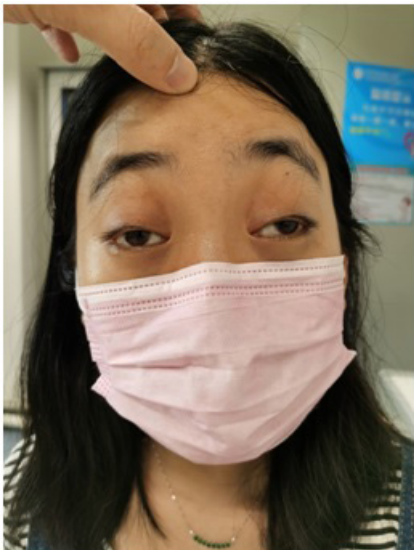

Figure 1: The frontal appearance of the patient.

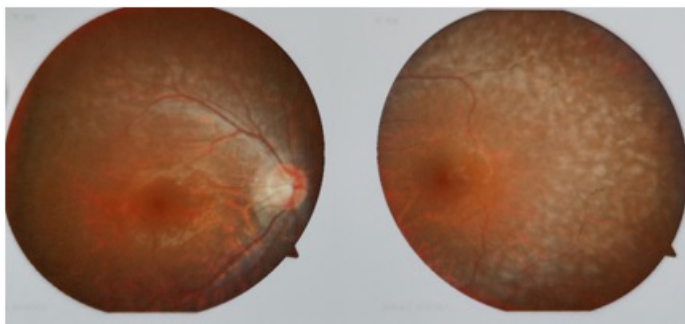


Figure 2: The fundus photograph of both eyes of the patient.

What's more, the examination of visual field revealed that both eyes were in tubular visual field, less than 10 degree. Examination of CT showed that both eyes were protrudent abnormally (Figure 3). The result of Electrocardiograms (ECG) was sinus rhythm, complete right bundle branch block and left anterior branch

block. The level of TSH was 12.202 mIU/L (the normal level was 0.56~5.91 mIU/L). The level of blood sugar and the examination of brain MRI were normal. And the tension test was negative. In conclusion, the diagnoses of the patient were KSS, TAO and hypothyroidism after hyperthyroidism treatment.

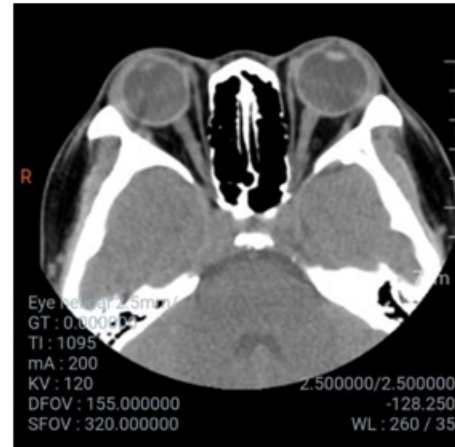

Figure 3: The image photograph of orbital CT on the plane of optic nerve.

3. Discussion and Conclusions

KSS was first reported by Kearns and Sayre in 1958. It is a mitochondrial encephalomyopathy caused by mitochondrial DNA genetic defects [2]. As a clinical subtype of CPEO, KSS has the following triad: onset before 20 years old, CPEO and pigmentary retinopathy. The affected individuals have at least one of the following conditions: complete heart block, cerebellar ataxia, Cerebrospinal Fluid (CSF) protein of more than 100 mg/dL, endocrine abnormalities, deafness, dementia and short stature [3]. The patient we presented had typical clinical triad and the diagnosis of KSS was certain. The thyroid dysfunction, bilateral proptosis and the thickened inferior rectus muscle of both eyes were consistent to the diagnosis of TAO [4].

TAO and MG are both autoimmune diseases. There are some correlations between them in pathogenesis. Most literatures discussed the clinical correlation between Graves' Disease (GD) and MG. It is reported that 5% of MG may develop with GD and 0.2% of GD may be complicated with MG [5]. The patient in our case with blepharoptosis and thymoma is easily misdiagnosed with TAO and MG. When it is hard to make a diagnosis, tension test should be considered as a further examination. The blepharoptosis and eyeball movement of patients with MG can be improved after proper treatment. MG was excluded in our patient because of no improvement of ptosis after thymectomy and tension test was negative. Muscle biopsies should be performed to exclude CPEO in MG patients with inconspicuous symptoms, slow progress and poor efficacy.

Clinically, the diagnostic criteria of TAO include orbital edema, proptosis and limited eyeball movement, accompanied by autoim-

immune characteristics and hyperthyroidism [4]. Combined with abnormal thyroid function and proptosis, the patient was diagnosed with TAO. As a result, the low visual acuity and the limitation of eyeball movement were easily mistaken having association with TAO. For patients with GD, especially those with ocular symptoms and signs, they should accept eye examination routinely. In our case, the binocular visual field was tubular. However, the thyroid-related extraocular muscle hyperplasia and the optic nerve changes caused by orbital apex pressing were not observed in CT examination. The low visual acuity and the fundus examination suggested pigmentary retinopathy. Therefore, we believed that binocular vision decline and visual field damage was related to pigmentary retinopathy.

The cardiac dysfunction in KSS patients is mostly showed as conduction block, including complete right bundle branch block and atrioventricular block [6]. Katsanos et al. reported a case of 18-year-old KSS female patient with degree I atrioventricular block, complete right bundle branch block and mitral valve hypertrophy prolapse who died of cardiac arrest finally [7]. And Kosinski et al reported that KSS might be complicated with left heart failure and cardiogenic cerebral infarction rarely, which resulted mild hemiplegia [8]. Importantly, the patients with KSS should take ECG examination to exclude from heart disease. ECG of our patient indicated complete right bundle branch block and left anterior branch block. We suggested her to follow up in cardiology department.

The common endocrine disorder in KSS patients is diabetes (12% - 15%), of which 50% belong to insulin-dependent type and it is related to family heredity, environment and personal living habits [6]. There are also rare cases of Addison's disease and anhidrosis, along with KSS [6,9]. However, the case of KSS with TAO has not been reported world-wide, so it has not attracted enough attention by clinicians. Both TAO and KSS are common in young women and cause eye movement disorders. They also result in visual acuity decline and visual field damage. Some patients of TAO may suffer from myasthenia gravis ptosis while ptosis is also discovered in patients with KSS. Consequently, the diagnosis and differential diagnosis of TAO and KSS is difficult.

KSS is a progressive disease and its prognosis varies according to various clinical symptoms. Some patients die of sudden syncope because of cardiac conduction block before 20 years old. At present, there is no effective treatment for KSS. Early diagnosis and early implantation of pacemaker can significantly improve the quality of life and prognosis. In addition, it is very important to recognize KSS with TAO which can promote early intervention for patients.

The clinical symptoms and signs of TAO and KSS are similar. They can occur alone or at the same time. The diagnosis and differential diagnosis are puzzling sometimes. Clinicians should pay

more attention to recognize them so as to take intervention early and improve their quality of life and prognosis.

References

1. Chaturvedi S, Bala K, Thakur R, Suri V. Mitochondrial encephalomyopathies: advances in understanding. *Med Sci Monit.* 2005; 11: 238-46.
2. Kearns TP, Sayre GP. Retinitis pigmentosa, external ophthalmoplegia, and complete heart block: unusual syndrome with histologic study in one of two cases. *AMA Arch Ophthalmol.* 1958; 60: 280-9.
3. Abu Diab A, AlTalbish A, Rosin B, Kanaan M, Kamal L, Swaroop A, et al. The combination of whole-exome sequencing and clinical analysis allows better diagnosis of rare syndromic retinal dystrophies. *Acta Ophthalmol.* 2019; 97: 877-86.
4. Bartley GB, Gorman CA. Diagnostic criteria for Graves' ophthalmopathy. *Am J Ophthalmol.* 1995; 119: 792-5.
5. Marino M, Barbesino G, Pinchera A, Manetti L, Ricciardi R, Rossi B, et al. Increased frequency of euthyroid ophthalmopathy in patients with Graves' disease associated with myasthenia gravis. *Thyroid.* 2000; 10: 799-2.
6. Yerdelen D, Koc F, Koc Z. Delayed diagnosis of Kearns-Sayre syndrome in a 38-year-old male patient: a case report. *Int J Neurosci.* 2008; 118: 267-75.
7. Katsanos KH, Pappas CJ, Patsouras D, Michalis LK, Kitsios G, Elisaf M, et al. Alarming atrioventricular block and mitral valve prolapse in the Kearns-Sayre syndrome. *Int J Cardiol.* 2002; 83: 179-81.
8. Kosinski C, Mull M, Lethen H, Töpper R. Evidence for cardioembolic stroke in a case of Kearns-Sayre syndrome. *Stroke.* 1995; 26: 1950-2.
9. Kane JM, Rossi J, Tsao S, Burton BK. Metabolic cardiomyopathy and mitochondrial disorders in the pediatric intensive care unit. *J Pediatr.* 2007; 151: 538-41.