

Facial Surgical Technique with Hybrid Laser

Arellano AH*, Arellano-Montalvo A and Arellano-Montalvo D

Department of Plastic and Reconstructive Surgery, Dermatology and Aesthetic Surgery Clinic of Puebla, México

*Corresponding author:

Dr. Aristides Arellano-Huacuja,
Department of Plastic and Reconstructive Surgery,
Dermatology and Aesthetic Surgery Clinic of
Puebla, México

Received: 02 Jan 2024

Accepted: 01 Feb 2024

Published: 06 Feb 2024

J Short Name: AJSCCR

Copyright:

©2024 Arellano AH, This is an open access article distributed under the terms of the Creative Commons Attribution License, which permits unrestricted use, distribution, and build upon your work non-commercially.

Citation:

Arellano AH. Facial Surgical Technique with Hybrid Laser. *Ame J Surg Clin Case Rep.* 2024; 7(11): 1-5

1. Introduction

We start performing the facial rejuvenation with the surgical procedure, SMAS plication and skin resurfacing in one surgical stage. However, it is needed between 2 to 3 weeks to recovery from the skin Resurfacing with HYBRID CO2 and Erbium 1570 laser. This procedure takes less recovery time and produces less edema, redness and patient discomfort. It is also carried up the Blepharoplasty in the upper eyelid and the transconjunctival approach in the lower eyelid with the CO2 laser in the cut mode.

2. Technique

Once the patient is marked in the places to be corrected, the procedure is started making the endovenus anesthesia combined with the local anesthesia (tumescent technique). Some patients ask for general anesthesia, in those cases special laser endo tracheal cannulas are used to ensure a more safety procedure. When local anesthesia has been placed in the neck, cheeks and the forehead, the cutting of pre- and post-auricular zone is started with the CO2 laser in the cut mode at a level of 6 Watts. The skin undermining is done using scissors, from the zygomatic arch to the nasolabial folds and the full neck. At the end, we check the hemostasia and the SMAS placcations are done with 3-0 Nylon. The excess skin is removed, and stitches are place in the area.

After finishing both sides of the face, the Blepharoplasty is performed. When skin excess is present in the upper eyelid, an incision with the CO2 laser in the cut mode is done. This allows removing the skin in a very easy way without bleeding, followed by the fat removal using also the laser at 6 Watts of energy. In the lower eyelid, the transconjunctival via is the technique we prefer for fat removal. The incision is made with the laser avoiding the presence of blood. The fat is taken out with fine forceps together with the CO2 laser. No skin is removed, and the incision is closed

with bringing near the borders, no suture is place. It is important to remember that all patients wear laser eye protectors to avoid eye damage. It is preferred to perform the lower eyelid by the transconjunctival approach because the orbicularis oculi muscle changes its fast fibers with the age, reducing the number of fibers and its size with the subsequent fibrous replacement. This changes in the musculature can produce round eye, change in the look expression, the sclera show, wrinkles, etc. With the transconjunctival approach the skin laxitude and wrinkles are corrected with the skin Resurfacing giving to the treated area a clear improvement. In all cases no skin excision was necessary.

If it is needed to perform an endoscopic forehead or a coronal approach, is possible to carry out the surgery and the skin resurfacing at the same time without complications. Laser Resurfacing is done with the Hybrid Lift program at 35 Co2 watts, Active time 1.0 and Energy 35 mj – HyGrid Ratio 2:1 Pixels 9x9 with cooling on – Single mode – Erbium 12.0 watts, Active time 3.0 and Energy 36 mj scan with the ProScan hand piece. The laser removes the skin layers by vaporization; therefore, it is important to know the amount of energy that is being transmitted to the skin surface in order to control the depth penetration and to avoid skin damage. Working with both laser technologies we have a full control of the temperature profile created in the tissue during skin rejuvenation procedures.

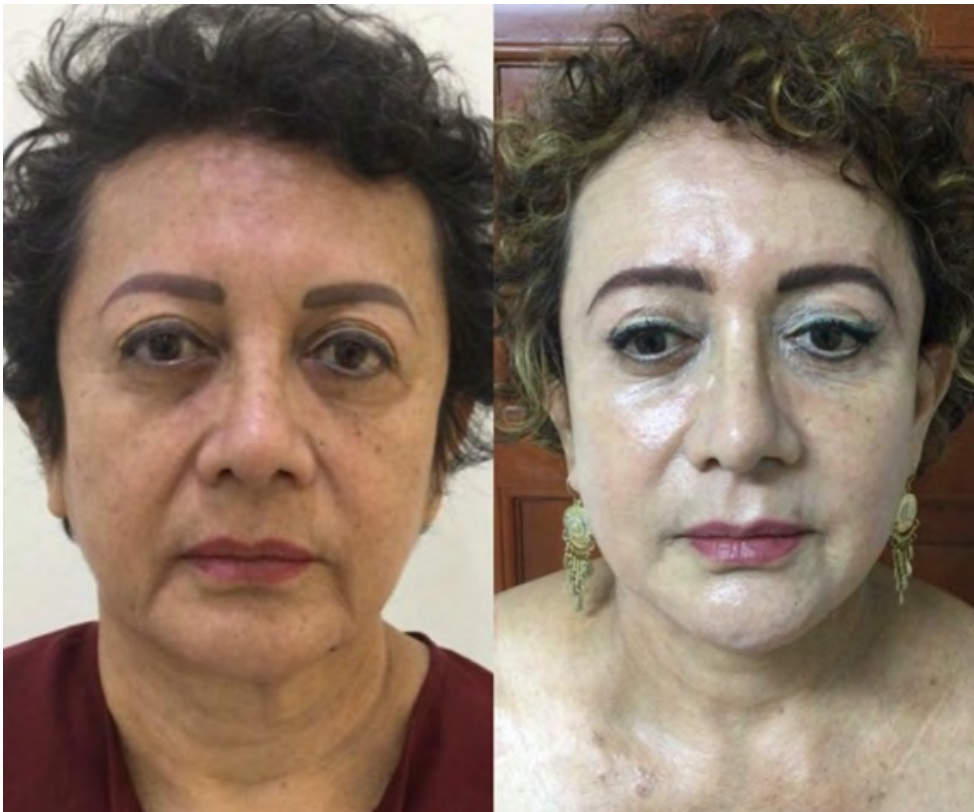Skin Resurfacing carried out with the CO2 10600 nm and Erbium 1570 nm lasers have been used in the forehead, the upper and lower eyelid, the internal and external Chantal of the eyes, the nose, the cheeks, the Perioral zone and the chin. In those zones sometimes we perform one or two passes. Permitting the treatment of fine and depth wrinkles, age spots, acne scars and photo aging. The laser is normally applied in the areas describe before during

the same procedure. The laser parameters are increase or decrease depending on the wrinkle's deepness, acne scars, skin sun damage, thickness, texture and color. In the first step, the laser is applied in the area to be treated. Once the first pass is finished, we lived the burn skin in place and perform the second step. Sometimes on the cross-feet or the Perioral area a third step is carried out.

As it was mentioned above, it is important to understand that the laser should be deeper in the central part of the face and lightly in the area where the surgical procedure was performed. In the cheeks were the SMAS plication and skin undermining was done. Employing the Hybrid Lift program on the skin flap there is no different skin color, texture or border remains by the change of laser. With this method the redness and changes in color pigmentation disappear at the same time in all the face, taking only 2 or 3

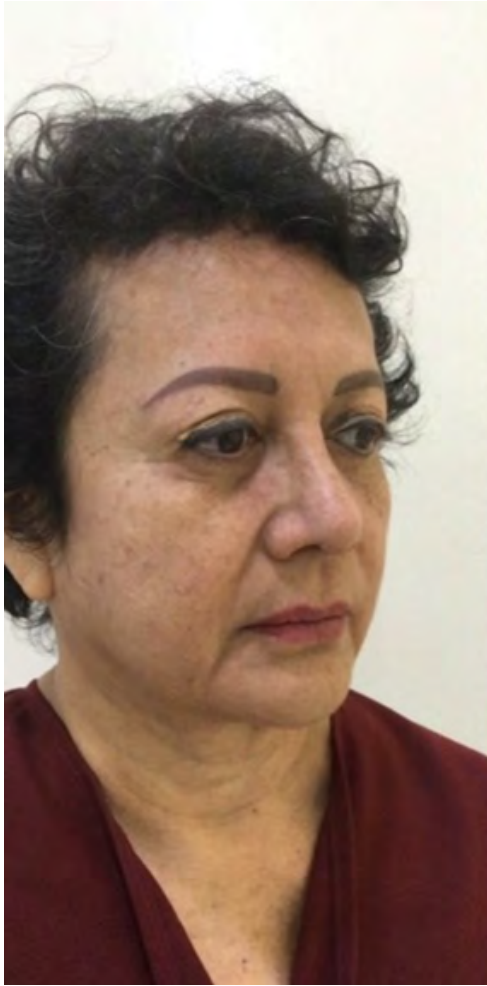
weeks for patient with skin type 3, 4 and 5 to get the natural skin color and texture.

When the procedure was done a Petrolatum cream with antibiotic is used two or three times a day. An occlusive bandage is used by 24 hrs. helping to heal the skin more quickly. The cream application is used for 8 days, followed by a moisturizing cream with sun blackout 100% in all the face during the morning. At night we recommend a cream mixed with sweet almonds, omega 6 acids, ceramide 934, silicone oils, aloe Vera and kojic acid helping to decrease the redness, dry skin discomfort and avoid de hyper pigmentation. With this combined technique the result is highly satisfactory because a face-lifting procedure is carried out in the areas where skin laxity is more often such as cheeks and neck. The skin Resurfacing method is used in those places where the surgery was not performed [1-8]



Frontal view Pre-op. 60 years old female patient

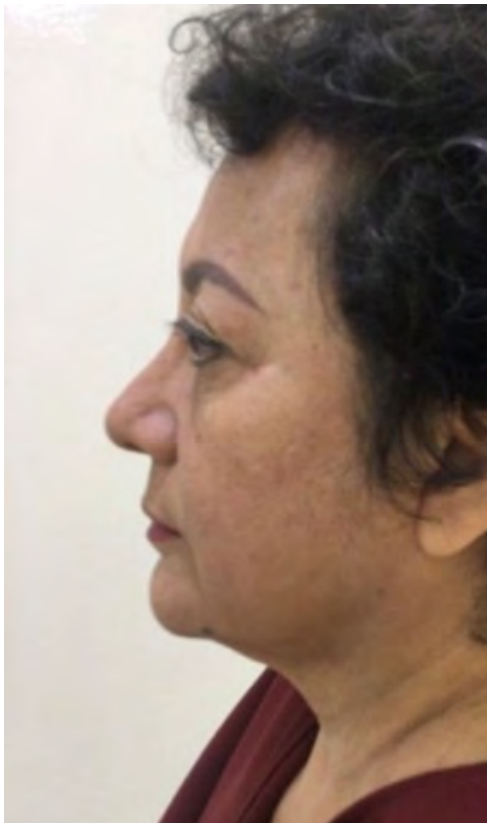Same view. Post-op Patient



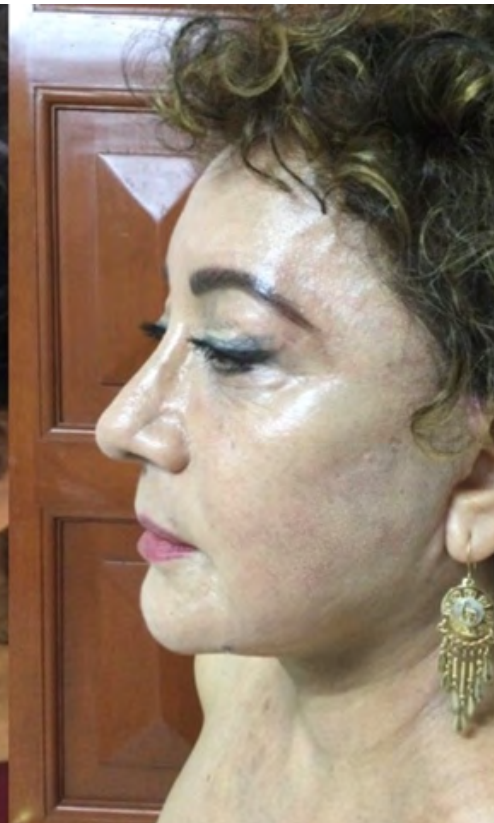Pre op oblique view



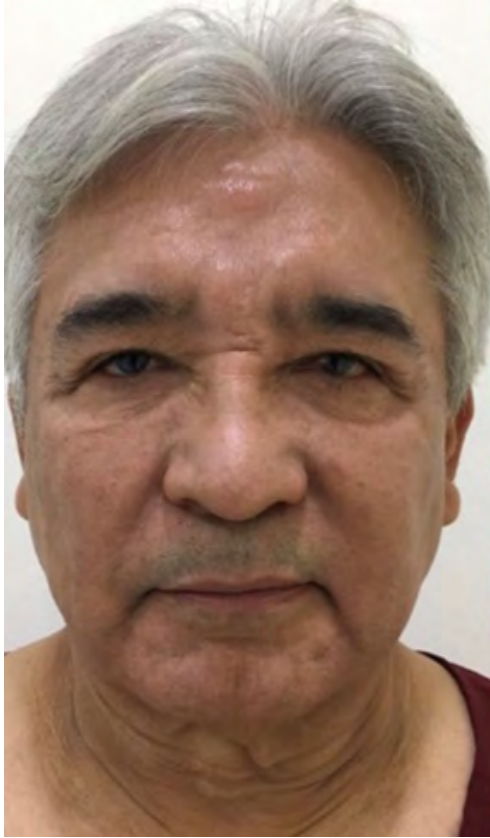Post op oblique view



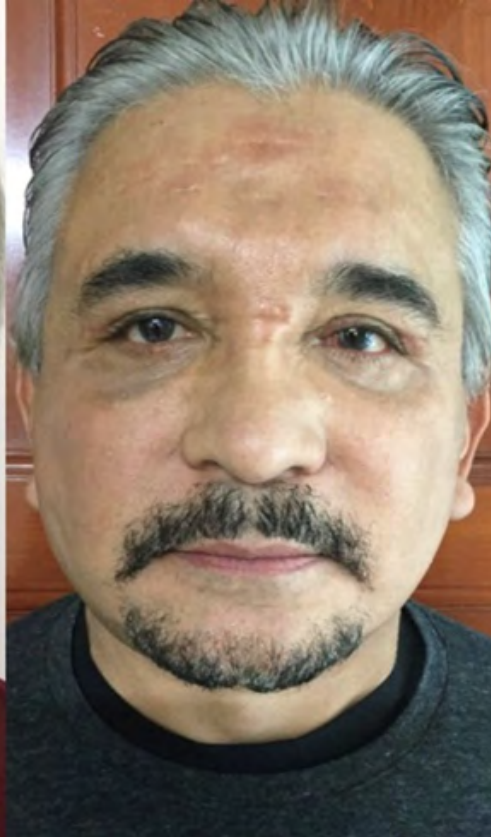Lateral view. Pre-op



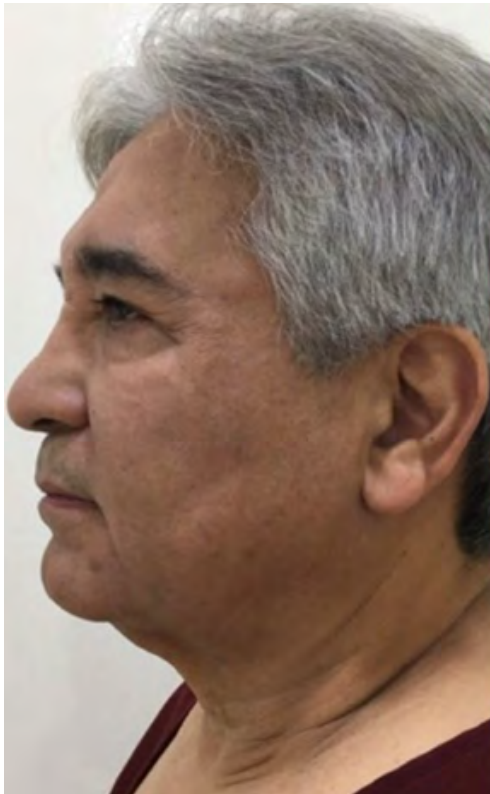Result one-month post-op.



Frontal view Pre-op. 60 years old male patient



Same view. Post-op Patient



Lateral view. Pre-op



Result one-month post-op.

3. Conclusion

We have seen that performing this procedure, the patient results are much better. If face lifting is carried out at the same surgical time with the skin resurfacing patient's recovery takes less time and discomfort. In 15 days, patient skin color is in the same tone. The skin looks much younger, smooth and facial rejuvenation is highly satisfactory. It is possible to perform different facial techniques at the same time.

References

1. Tessier P. The conjunctival approach to the orbital floor and maxilla in congenital malformations and trauma. *G Maxillofacial Surg.* 1973; 1:3.
2. Shapahay SM, Strong MS, Anastasi GW. Removal of rhinophyma with the carbon dioxide laser. A preliminary report. *Arch Otolaryngol.* 1980; 106: 257-9.
3. Fitzpatrick RE, Ruiz-Esparza J, Goldman MP. The depth of thermal necrosis using the CO2 laser: a comparison of the superpulsed mode and conventional mode. *J Dermatol Surg Oncol.* 1991; 17: 340 -4.
4. Zweig AD, Meierhofer B, Muller OM. Lateral damage along pulsed laser incisions. *Lasers Surg Med.* 1990; 262-74.
5. Weinstein C. Ultrapulse carbon dioxide laser removal of periocular wrinkles in association with laser Blepharoplasty. *J Clin Laser Med Surg.* 1994; 12: 205-9.
6. Weinstein C, Alster TS. Cutaneous laser resurfacing. In: Alster TS, Apfelberg DB, eds. *Cosmetic Laser Surgery.* New York: John Wiley & Sons, 1996-27.
7. Fitzpatrick RE, Goldman MP, Ruiz-Esparza J. Clinical advantage of the CO2 laser superpulsed mode. Treatment of verruca vulgaris, seborrheic keratoses, lentiginos, and actinic cheilitis. *J Dermatol Surg Oncol.* 1994; 20: 449-56.
8. Ginsbach G. Periorbital aesthetic surgery with KTP-laser presented at Laser Med 93, International Kongress Laser Medicin, Munich, Germany 1993.